



Prevalence of Variations in the Lingual Foramina – A CBCT Study

Jones Jayabalan¹, M.R. Muthusekhar², Arvind Muthukrishnan³

¹Postgraduate Student, Department of Oral and Maxillofacial Surgery, Saveetha Dental College and Hospitals, Saveetha Institute of Medical and Technical Sciences, Chennai, India.

²Program Director, Department of Oral and Maxillofacial Surgery, Saveetha Dental College and Hospitals, Saveetha Institute of Medical and Technical Sciences, Chennai, India.

³Head of the Department, Department of Oral Medicine and Radiology, Saveetha Dental College and Hospitals, Saveetha Institute of Medical and Technical Sciences, Chennai, India.

Abstract

To assess the prevalence of variations in the lingual foramina in the anterior mandible mid line region among people coming to our institute. 70 CBCT images of mandible taken at Saveetha Dental College, Chennai (35 male, 35 female) were evaluated on the axial, coronal and sagittal sections for the presence and number of lingual foramina for each patient. Their patterns, length, distance from the alveolar crest and distance from the inferior border of the mandible were measured. The study data was analysed in the year 2019. Sample size estimation: Sample size estimation was done and the minimum sample size of both groups was calculated, following these input conditions: power of 0.95 and $P \leq 0.05$ sample size arrived at 35 per group. Statistical analysis used: Descriptive statistics frequency analysis was used. Results: The mean age group of the male population was 32 years and the mean age group of the female population was 38 years. All the 70 CBCT images analysed showed at least one lingual foramina. 38 images showed presence of one single lingual foramina of which 22 were male and 16 were female. 30 images showed presence of two lingual foramina of which 12 were male and 18 were female. Two images showed the presence of three lingual foramina of which one in male and one in female. Within the limitations of this study, it can be concluded that there was a significant anatomical variations are common in lingual foramen. Anatomical variations cannot be identified in 2D imaging. Common anatomical alteration is the presence of 2nd Foramina.

ARTICLE HISTORY

Received February 16, 2020
Accepted March 12, 2020
Published October 14, 2020

KEYWORDS

Anterior mandible, lingual foramen, cone beam computed tomography, surgical complications, dental implants.

INTRODUCTION

It is popularly known intra bony vascular canal, it is one of the few anatomical landmark present in anterior mandible which was named the lingual foramen and mandible incisive canal (MIC) (1-3). The lingual foramen is located in the mandible's midline, at the inferior or superior level to mental spines (4). Such anatomical landmarks that are present in the anterior jaw have recovered the focus on avoiding complexities and enhancing the surgical planning (5). The intermental foramen area of mandibular is usually said to be a protective region that includes some of the risk damages to the major anatomic at surgical process. Although such safety suggestions does not depend upon the course of several anatomical landmarks and knowledge of place (6). At

the time of anterior dental surgery (grafting procedures, implant placement, or genioplasty procedure), the lingual foramen descriptions and its bony canal locations and dimensions are considered significantly in order to avoid other different complexities (7). The following are the several complexities namely pulp canal obliteration, intraoperative bleeding, and neuropraxia of mandibular incisive nerve, nerve injury, and intraoperative bleeding. The reported long and short term disturbances of neurosensory contain inexistence of pulp sensitivity or alteration in the lower front teeth (8,9). Today dental implants are considered to be the basic choice for edentulous patient's prosthetic rehabilitation. In many cases, the implant placement is said to be the predictable

Contact: Jones Jayabalan Saveetha Dental College, Saveetha Institute of Medical and Technical Sciences

jonescyril27@gmail.com Tel: +91 7845619673

2020 The Authors. This is an open access article under the terms of the Creative Commons Attribution Non Commercial Share Alike 4.0 (<https://creativecommons.org/licenses/by-nc-sa/4.0/>).

and routine method ⁽¹⁰⁾. In several conditions, haemorrhagic episodes that threatens life may happen because of the lingual cortex perforation when keeping the dental implants in the mandible anterior. Few studies showed that when the lingual periosteal is broken, a hematoma is massively developed in this area and swelling of mouth floor is develop which lead to upper airway obstruction ⁽¹⁰⁻¹³⁾. Therefore, it is essential to perform cautious preoperative planning that involves radiological picturing ⁽⁷⁾. Cone-beam computed tomography (CBCT) has been indicated as the superior than panoramic radiographs in representing the mandibular lingual foramen and its bony canal differences. CBCT's image quality and its lower cost and dose than the traditional computed tomography enabled more reachable craniofacial structure's three dimensional evaluation in the dental practice ⁽¹⁴⁾. CBCT enables relatively more resolution (0.1 mm homogeneous voxel spatial resolution) when compared to spiral CT, ⁽¹⁵⁾ which was carried out by Liang et al. to evaluate the inferior and superior genial spinal canals and foramina in study ⁽¹⁶⁾. Sheikhi et al. ⁽¹⁷⁾ suggested to utilize CBCT imaging in the preoperative assessment before setting up the dental implants. Lingual foramen transfers the neurovascular bundles for the nearby structures; therefore some damages in the lingual foramen at the time of surgical procedures can cause neurosensory disturbance and/or haemorrhage. Hence, it is default dentist known about the structures in the anterior mandible while contemplating other implant planning or surgical procedures. Thus, CBCT has important part in the surgical procedures and implant planning in dentistry ⁽¹⁸⁾. The implant placements success relies on the radiological assessment that supports the clinician in assessing the implant placement parameter by showing the structure such as foramen, course of nerves, alveolar bone's shape and size and so on. This study aims to evaluate the occurrence of differences in lingual foramina that is present in the mid line area of anterior mandible within the people.

SUBJECTS AND METHODS

Sample size estimation was done and the minimum sample size of both groups was calculated, following these input conditions: power of 0.95 and $P \leq 0.05$ sample size arrived at 35 per group. Seventy CBCTs images of mandible taken using Sirona Orthopos at Saveetha Dental College, Chennai (35 male, 35 female) were evaluated on the axial, coronal and sagittal sections for the presence

and number of lingual foramina for each patient. The patterns of the foramina, their length, distance from the alveolar crest to the foramina and distance from the foramina to the inferior border of the mandible were measured as shown in Figure 1. The study datas was analysed in the year 2019.

Ethical Clearance

Approval was obtained from the Institutional Review Board of Saveetha Institute of Medical and Technical Science, India.

Inclusion criteria

1. Age more than 18 years.
2. CBCT images involving mandible.

Exclusion criteria

1. Syndromic patients and congenital deformity cases.
2. History of trauma, pathology, surgery involving mandible.
3. Distorted or blurred CBCT images.
4. Patient under orthodontic treatment CBCT.
5. Patient with dental implants in the anterior mandible region.

Randomization was done well in advance by a third person who was not related to the study. Computer-generated random numbers were used for simple randomization of CBCT images. Sequentially numbered, opaque sealed envelopes (SNOSE) method was used to effectively conceal the randomization sequence. The computer generated method is random and had an equal chance of occupying the position. Therefore, based on the result, a group was assigned.

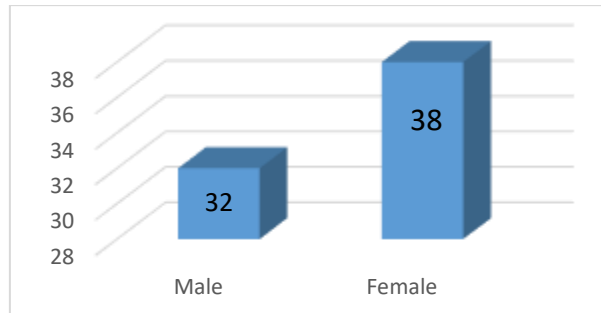
Assessment

1. Mean age of Subjects based on gender.
2. Number of Lingual Foramina according to gender.
3. The Patterns of the lingual foramina.
4. The Mean Course length of the foramina
5. The Mean Distance of the foramina from the alveolar crest
6. The Mean distance of the foramina from the inferior border of the mandible

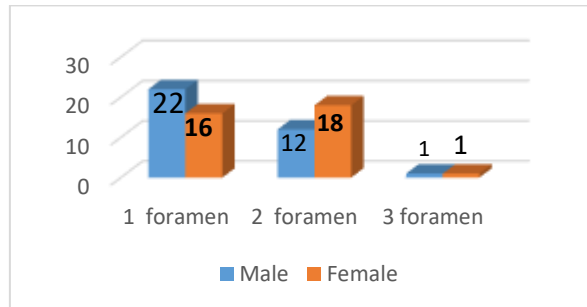
STATISTICS

The collected data were analysed with IBM.SPSS statistics software 23.0 Version. To describe the data descriptive statistics frequency analysis, percentage analysis were used for categorical variables and the mean & S.D were used for continuous variables.

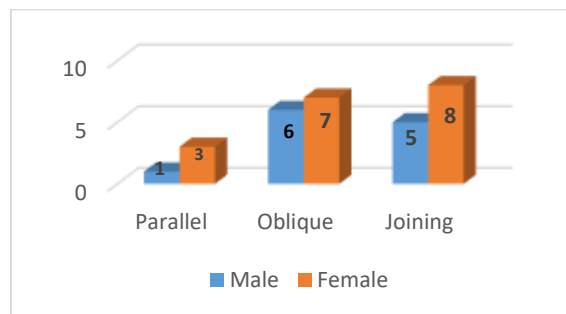
Results



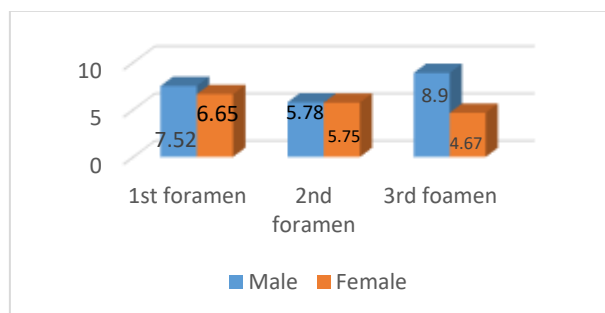
Graph 1: Mean age of Subjects based on gender



Graph 2: Number of Lingual Foramina according to gender

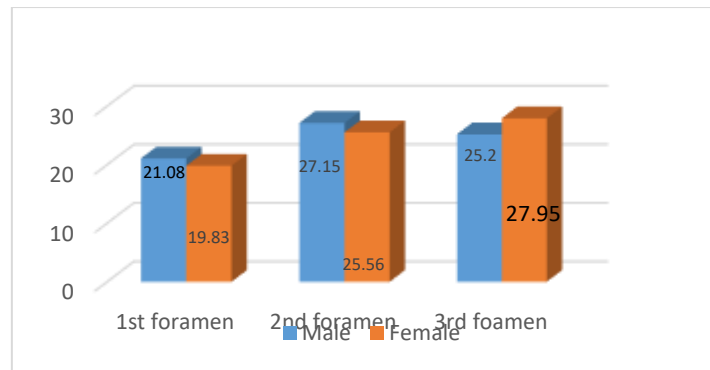


Graph 3: The Patterns of the lingual foramina observed

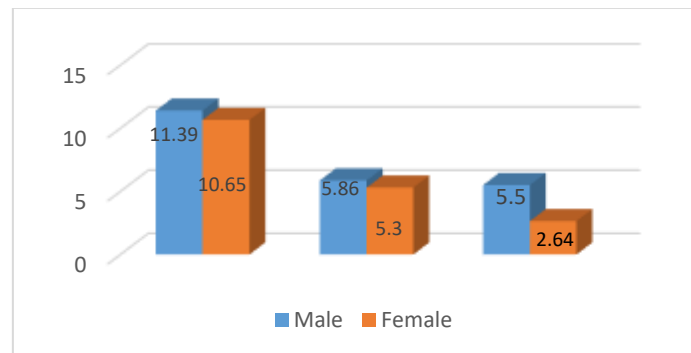


Graph 4: The Mean Course length of the foramina

Variations in lingual foramina



Graph 5: The Mean Distance of the foramina from the crest



Graph 6: The Mean distance of the foramina from the inferior border

The mean age group of the male population was 32 years and the mean age group of the female population was 38 years. All the 70 CBCT images analysed showed at least one lingual foramina. 38 images showed presence of one single lingual foramina (Figure 1) of which 22 were male and 16 were female. 30 images showed presence of two lingual foramina (Figure 2) of which 12 were male and 18 were female. Two images showed the presence of three lingual foramina (Figure 3) of which one in male and one in female.

In multiple foramina they had a parallel, oblique or joining pattern. In case of two foramina, four had parallel pattern, thirteen had oblique pattern and joining pattern. In case of three foramina, one had an oblique pattern and one had a joining pattern.

The average distance of the 1st foramina from the alveolar crest was 21.08mm in males and in female it was 19.83 mm. The average distance of the 2nd foramina from the alveolar crest was 27.15 mm in males and 25.56 mm in females. The distance of the 3rd foramina from the alveolar crest was 25.2 mm in males and 27.95 mm in females. The average distance from the 1st foramina to the inferior border of the mandible was 11.39mm in males and in females .05 mm. The average distance from the 2nd foramina to the inferior border of the mandible was 5.86mm in males and 5.3 mm in females. The distance from the 3rd foramina to the inferior border of the mandible was 5.3mm in males and

2.64mm in females. All the measurements were done in the sagittal section view as shown in the figure 4.

DISCUSSION

Having maximum utilization of grafting procedures and implant procedures to the anterior jaw bone, numerous reports expressed that postoperative complaints are increasing (5). The textbooks on dental anatomy comparatively fail to state about the lingual foramen's presence. Although, the lingual foramen is said to be stated better about the oral radiographs and therefore clearly explained in the textbooks associated with radiographic anatomy (19). The lingual foramen knowledge might be significant for the presurgical implant set up consideration in the mandible's midline. This foramen's content has been a debate matter. Several of the studies think that the content of vascular is being the anastomosis in the left and right lingual arteries sublingual branch. The artery might have enough size to stimulate in the relative soft tissues or haemorrhage intraosseously which could be complex to control (20,21). Past studies have been carried out in terms of diameter, frequency, and other lingual foramen and their canal's anatomical features. The purpose of the present study was to investigate the prevalence and anatomical variations of lingual foramen among Chennai patients.

In this study, 70 mandibles were investigated and all of the images had at least one lingual foramen. The outcomes help those studies of Tepper et al. (2) Gahleitner et al. (1) and Mc Donnell (22). However, the outcomes give no proofs to those study of Jacob et al where the lingual foramen was viewed in 82% of images of spiral CT (23). A possible description for the given discrepancy is, the restructuring procedure using few CT scans insufficient in restricted cross-sectional slice appropriately in midline of the mandibular. However, early cadaveric studies were there which explained the anterior lingual foramen presence (24), the CT advent and then the technology of Cone-beam CT (CBCT) have viewed more interest in the anterior linguae's location, prevalence, and number (1,7,16,25-27). The CBCT provides three-dimensional radiographic imaging by the highly decreased radiation doses (when compared with traditional CT) and is turning into a regular diagnostic instrument for implant intending. The anterior lingual foramen's location and occurrence have been investigated in the dried mandibles and using the CBCT and CT scans (1,7,16,25-30).

and 45 males) on the coronal, curved, and axial sections for existence and total lingual foramina for all the patients. 30 images showed presence of two lingual foramina of which 12 were male and 18 were female. Two images showed the presence of three lingual foramina of which one in male and one in female. Likewise, the study by Sheikhi et al. (17) represented two lingual foramens are 52.9% common, this was even represented in past studies (32,33). Although, the outcomes are in conflict with Liang et al. and Tepper et al. studies outcomes, in which, they identified single foramen was highly common (2,7). Only the patients that have single lingual foramen (24.5 percent incidence in the study) will be beneficial from the foramen's inferior location, enabling closer implant placement or flap surgery having no damage risks for the canal. Contrarily, Sheikhi et al. (17) Showed that at least four lingual foramen are detected, that helps the Katakami et al. (34) studies. The data show that only one midline lingual foramen is there (24.5 percent), it was generally more than the genial spine. From the clinical perception, not the number but the location of the midline lingual foramina is said to be significant for neglecting the complexities.

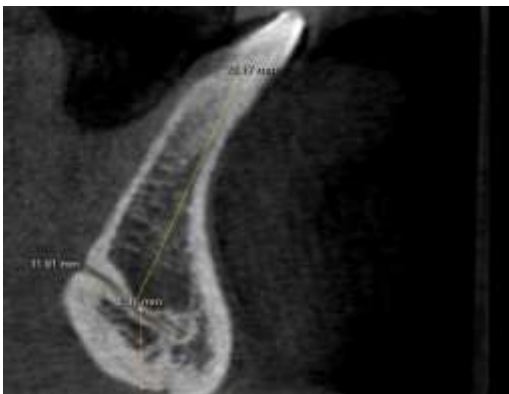

Figure 1 : One foramen CBCT view (sagittal section)

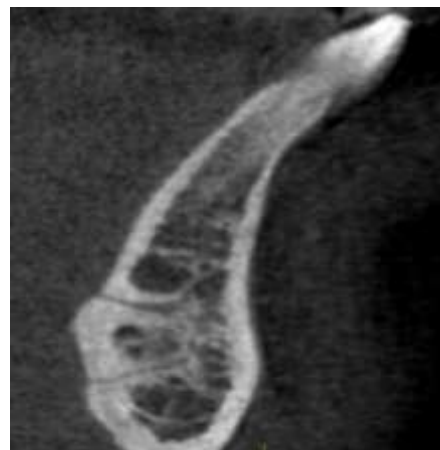

Figure 3: Three foramen CBCT (sagittal section)

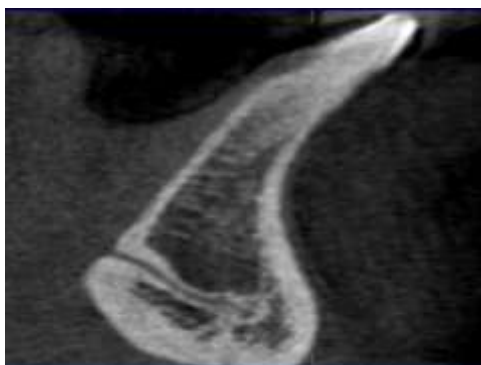

Figure 2: Two Foramen CBCT view (sagittal section)

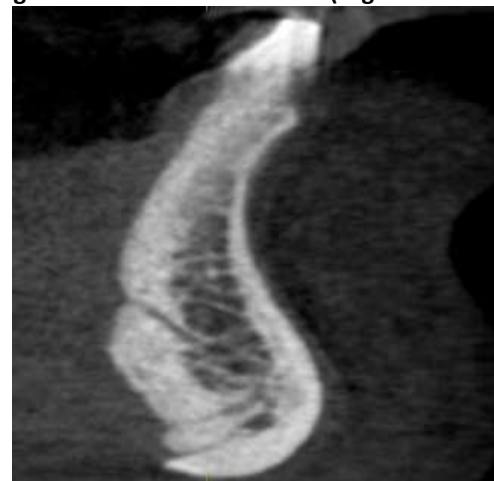


Figure 4: Measurements done from crest and inferior border of the mandible

In the finding, it is noted that 38 images showed presence of single lingual foramina of which 22 are male and 16 were female. Similar to this, Assari et al. (31) represented the 160 images of CBCT of the Saudi individual's mandible taken in the dental center called Riyadh were assessed (112 females

In multiple foramina they had a parallel, oblique or joining pattern. In case of two foramina, four had parallel pattern, thirteen had oblique pattern and joining pattern. In case of three foramina, one had an oblique pattern and one had a joining pattern. Nortie et al. ⁽³⁵⁾ and Langlais et al. ⁽³⁶⁾ studies categorized the mandibular canal bifurcation's pattern into four kinds: type1: the origination of two canals is from a single foramen. Type2: The small supplemental upper canal lengthening to third or second molar. Type3: both the mandibular ramus with same dimensions actually coming up from individual foramina in mandibular ramus and combining to make a single canal in molar area. Type4: the supplemental canal coming up in Retromolar pad area and combining with the major canals in Retromolar region.

Our study finding revealed that the average distance of the 1st foramina from the alveolar crest was 21.08mm in males and in female it was 19.83 mm. The average distance of the 2nd foramina from the alveolar crest was 27.15 mm in males and 25.56 mm in females. The distance of the 3rd foramina from the alveolar crest was 25.2 mm in males and 27.95 mm in females. The average distance from the 1st foramina to the inferior border of the mandible was 11.39mm in males and in females .05 mm. The average distance from the 2nd foramina to the inferior border of the mandible was 5.86mm in males and 5.3 mm in females. The distance from the 3rd foramina to the inferior border of the mandible was 5.3mm in males and 2.64mm in females. In 2012 previous studies, Gosavi & Vatsalawamy ⁽³⁷⁾ computed as 69.37 mm, Sengul and Kodioglu et al. ⁽³⁸⁾ computed as 74.6 mm and Sharma et al. ⁽³⁹⁾ noticed 68 and 77 mm for female and male Punjabi population. Kandziora et al. ⁽⁴⁰⁾ computed 25.3±2.22 mm in Korian population. Konig et al noticed the average transverse diameter value of left and right side superior articular facet as 11.2±1.5 and 11.6±2.0 mm in the population of Germany. Gosavi & Vatsalawamy ⁽³⁷⁾ assess the superior articular facet's transverse diameter value as 10.47±1.61 and 10.36±1.72 mm. Kaur et al assess the AP diameter's mean value of left and right side of inferior articular facet as 17.70 ±1.60 and 17.54±1.50 mm and to transverse diameter it was 14.94±1.51 and 14.99±1.65mm, Gosavi & Vatsalawamy ⁽³⁷⁾ computed it to be 7.4±1.67 and 7.13±1.0 mm for left and right A-P diameter and for left and right transverse diameter it was 14.42± 1.67mm and 14.01 ±1.93mm. Moreover the study by Patel & Gupta ⁽⁴¹⁾ assessed the mean distance between lateral margins of both transverse foramina was 55.48 mm and the inner distance was 44.77 mm. The mean for anteroposterior diameter of vertebral canal of atlas was 28.16mm and transverse diameter was 26.63 mm. The diameter of the inferior lingual foramen is lesser than superior

lingual foramen. The inferior and superior lingual foramen's average diameter in the observation was 0.9 (SD 0.39) mm and 1.12 (SD 0.4) mm, whereas, in the past studies it was 0.8 (SD 0.4) mm and 0.9 (SD 0.4) mm ⁽⁴²⁾. However, the diameter of the smaller canals is lesser than 1mm and are uncommon in producing vital hematoma, huger canals might be indicated in the radiologic reports and deliberated in the preoperative planning process.

Several differences in the referred anatomical landmarks were found in the current study in relation with past studies. Because of such findings, recommendations are given as per various measurements and anatomical positions for the lingual foramen and their bony canal in all the individuals, it is vital to think the given point at the time of preoperative planning to the surgery and particularly to transplant placement in anterior mandible. Moreover, the imaging of CBCT can represent the lingual foramen and their bony canal's anatomical features in order to neglect the postoperative complexities.

CONCLUSION

Within the limitations of this study, it can be concluded that there was a significant anatomical variations are common in lingual foramen. Anatomical variations cannot be identified in 2D imaging. Common anatomical alteration is the presence of second Foramina.

REFERENCES

- Gahleitner A, Hofschneider U, Tepper G, Pretterklieber M, Schick S, Zauza K, et al. Lingual Vascular Canals of the Mandible: Evaluation with Dental CT. *Radiology* [Internet]. 2001 Jul;220(1):186-9. Available from: <http://pubs.rsna.org/doi/10.1148/radiology.220.1.r01j105186>
- Tepper G, Hofschneider U, Gahleitner A, Ulm C. Computed tomographic diagnosis and localization of bone canals in the mandibular interforaminal region for prevention of bleeding complications during implant surgery. *Int J Oral Maxillofac Implant* [Internet]. 2001;16(1):68-72. Available from: <https://www.ncbi.nlm.nih.gov/pubmed/11280364>
- Mardinger O, Chaushu G, Arensburg B, Taicher S, Kaffe I. Anatomic and radiologic course of the mandibular incisive canal. *Surg Radiol Anat* [Internet]. 2000 Dec;22(3-4):157-61. Available from: <http://link.springer.com/10.1007/s00276-000-0157-5>
- McDonnell D, Reza NM, Todd M. The mandibular lingual foramen: a consistent arterial foramen in the middle of the mandible. *J Anat*. 1994;184(2):363-9.

5. Jacobs R, Lambrichts I, Liang X, Martens W, Mraiwa N, Adriaensens P, et al. Neurovascularization of the anterior jaw bones revisited using high-resolution magnetic resonance imaging. *Oral Surgery, Oral Med Oral Pathol Oral Radiol Endodontology* [Internet]. 2007 May;103(5):683-93. Available from: <http://linkinghub.elsevier.com/retrieve/pii/S1079210406008778>
6. Pommer B, Tepper G, Gahleitner A, Zechner W, Watzek G. New safety margins for chin bone harvesting based on the course of the mandibular incisive canal in CT. *Clin Oral Implants Res*. 2008 Dec;19(12):1312-6.
7. Liang X, Jacobs R, Lambrichts I, Vandewalle G. Lingual foramina on the mandibular midline revisited: A macroanatomical study. *Clin Anat* [Internet]. 2007 Apr;20(3):246-51. Available from: <http://doi.wiley.com/10.1002/ca.20357>
8. Sbordone L, Menchini-Fabris GB, Toti P, Sbordone C, Califano L, Guidetti F. Clinical survey of neurosensory side-effects of mandibular parasymphyseal bone harvesting. *Int J Oral Maxillofac Surg* [Internet]. 2009 Feb;38(2):139-45. Available from: <http://linkinghub.elsevier.com/retrieve/pii/S0901502708003949>
9. Hirsch J-M, Brånemark P-I. Fixture stability and nerve function after transposition and lateralization of the inferior alveolar nerve and fixture installation. *Br J Oral Maxillofac Surg* [Internet]. 1995 Oct;33(5):276-81. Available from: <http://linkinghub.elsevier.com/retrieve/pii/0266435695900373>
10. Del Castillo-Pardo de Vera JL, López-Arcas Calleja JM, Burgueño-García M. Hematoma of the floor of the mouth and airway obstruction during mandibular dental implant placement: a case report. *Oral Maxillofac Surg* [Internet]. 2008 Dec 30;12(4):223-6. Available from: <http://link.springer.com/10.1007/s10006-008-0134-4>
11. Kalpidis CDR, Setayesh RM. Hemorrhaging Associated With Endosseous Implant Placement in the Anterior Mandible: A Review of the Literature. *J Periodontol* [Internet]. 2004 May;75(5):631-45. Available from: <http://doi.wiley.com/10.1902/jop.2004.75.5.631>
12. Woo BM, Al-Bustani S, Ueek BA. Floor of mouth haemorrhage and life-threatening airway obstruction during immediate implant placement in the anterior mandible. *Int J Oral Maxillofac Surg* [Internet]. 2006 Oct;35(10):961-4. Available from: <http://linkinghub.elsevier.com/retrieve/pii/S0901502706001640>
13. Mraiwa N, Jacobs R, Steenberghe D, Quirynen M. Clinical Assessment and Surgical Implications of Anatomic Challenges in the Anterior Mandible. *Clin Implant Dent Relat Res* [Internet]. 2003 Dec;5(4):219-25. Available from: <http://doi.wiley.com/10.1111/j.1708-8208.2003.tb00204.x>
14. de Oliveira-Santos C, Souza PHC, de Azambuja Berti-Couto S, Stinkens L, Moyaert K, Rubira-Bullen IRF, et al. Assessment of variations of the mandibular canal through cone beam computed tomography. *Clin Oral Investig*. 2012 Apr;16(2):387-93.
15. Uchida Y, Noguchi N, Goto M, Yamashita Y, Hanihara T, Takamori H, et al. Measurement of Anterior Loop Length for the Mandibular Canal and Diameter of the Mandibular Incisive Canal to Avoid Nerve Damage When Installing Endosseous Implants in the Interforaminal Region: A Second Attempt Introducing Cone Beam Computed Tomography. *J Oral Maxillofac Surg*. 2009 Apr;67(4):744-50.
16. Liang X, Jacobs R, Lambrichts I. An assessment on spiral CT scan of the superior and inferior genial spinal foramina and canals. *Surg Radiol Anat*. 2006 Mar;28(1):98-104.
17. Sheikhi M, Mosavat F, Ahmadi A. Assessing the anatomical variations of lingual foramen and its bony canals with CBCT taken from 102 patients in Isfahan. *Dent Res J* [Internet]. 2012;9(1):S45-S51. Available from: <https://www.ncbi.nlm.nih.gov/pmc/articles/PMC3692199/>
18. Denny CE, Natarajan S, Ahmed J, Binnal A. Anatomic Variation in Lingual Foramen: A Cone beam Computed Tomography Study. *Patil S, editor. World J Dent*. 2016;7(4):179-81.
19. Mraiwa N, Jacobs R, Moerman P, Lambrichts I, van Steenberghe D, Quirynen M. Presence and course of the incisive canal in the human mandibular interforaminal region: two-dimensional imaging versus anatomical observations. *Surg Radiol Anat* [Internet]. 2003 Dec 11;25(5-6):416-23. Available from: <http://link.springer.com/10.1007/s00276-003-0152-8>
20. Darriba MA, Mendonça-Caridad JJ. Profuse bleeding and life-threatening airway obstruction after placement of mandibular dental implants. *J Oral Maxillofac Surg* [Internet]. 1997 Nov;55(11):1328-30. Available from: <http://linkinghub.elsevier.com/retrieve/pii/S0278239197901956>.
21. Givol N, Chaushu G, Halamish-Shani T, Taicher S. Emergency Tracheostomy Following Life-Threatening Hemorrhage in the Floor of the Mouth During Immediate Implant Placement in the Mandibular Canine Region. *J Periodontol*

- [Internet]. 2000 Dec;71(12):1893–5. Available from: <http://doi.wiley.com/10.1902/jop.2000.71.12.1893>
22. Hofschneider U, Tepper G, Gahleitner A, Ulm C. Assessment of the blood supply to the mental region for reduction of bleeding complications during implant surgery in the interforaminal region. *Int J Oral Maxillofac Implant.* 1999;14(3):379–83.
 23. Almasri M, El-Hakim M. Fracture of the anterior segment of the atrophic mandible related to dental implants. *Int J Oral Maxillofac Surg.* 2012 May;41(5):646–9.
 24. Liang H, Frederiksen N, Benson B. Lingual vascular canals of the interforaminal region of the mandible: evaluation with conventional tomography. *Dentomaxillofac Radiol.* 2004 Sep;33(5):340–1.
 25. Lustig JP, London D, Dor BL, Yanko R. Ultrasound identification and quantitative measurement of blood supply to the anterior part of the mandible. *Oral Surgery, Oral Med Oral Pathol Oral Radiol Endodontology* [Internet]. 2003 Nov;96(5):625–9. Available from: <http://linkinghub.elsevier.com/retrieve/pii/S107921040300516X>
 26. Scaravilli MS, Mariniello M, Sammartino G. Mandibular lingual vascular canals (MLVC): Evaluation on dental CTs of a case series. *Eur J Radiol.* 2010 Nov;76(2):173–6.
 27. Assari A, Almashat H, Alamry A, Algarni B. Prevalence and location of the anterior lingual foramen: A cone-beam computed tomography assessment. *Saudi J Oral Sci.* 2017;4(1):41.
 28. von Arx T, Matter D, Buser D, Bornstein MM. Evaluation of Location and Dimensions of Lingual Foramina Using Limited Cone-Beam Computed Tomography. *J Oral Maxillofac Surg* [Internet]. 2011 Nov;69(11):2777–85. Available from: <http://linkinghub.elsevier.com/retrieve/pii/S0278239111011244>
 29. Rosano G, Taschieri S, Gaudy JF, Testori T, Del Fabbro M. Anatomic assessment of the anterior mandible and relative hemorrhage risk in implant dentistry: a cadaveric study. *Clin Oral Implants Res.* 2009 Aug;20(8):791–5.
 30. Katakami K, Mishima A, Kuribayashi A, Shimoda S, Hamada Y, Kobayashi K. Anatomical characteristics of the mandibular lingual foramina observed on limited cone-beam CT images. *Clin Oral Implants Res* [Internet]. 2009 Apr;20(4):386–90. Available from: <http://doi.wiley.com/10.1111/j.1600-0501.2008.01632.x>
 31. Nortjé CJ, Farman AG, Grotepass FW. Variations in the normal anatomy of the inferior dental (mandibular) canal: A retrospective study of panoramic radiographs from 3612 routine dental patients. *Br J Oral Surg* [Internet]. 1977 Jul;15(1):55–63. Available from: <https://linkinghub.elsevier.com/retrieve/pii/0007117X77900087>
 32. Langlais RP, Broadus R, Glass BJ. Bifid mandibular canals in panoramic radiographs. *J Am Dent Assoc* [Internet]. 1985 Jun;110(6):923–6. Available from: <https://linkinghub.elsevier.com/retrieve/pii/S0002817785060196>
 33. Gosavi SN, Vatsalaswamy P. Morphometric Study of the Atlas Vertebra using Manual Method. *Malaysian Orthop J* [Internet]. 2012 Jul 1;6(3):18–20. Available from: <http://www.morthoj.org/2012/v6n2/Morphometric-Study-of-the-Atlas-Vertebra.pdf>
 34. Sengul G, Kadioglu HH. Morphometric Anatomy of the Atlas and Axis Vertebrae. *Turk Neurosurg* [Internet]. 2006;16(2):69–76. Available from: https://www.researchgate.net/publication/290528448_Morphometric_anatomy_of_the_atlas_and_axis_vertebrae
 35. Sharma T, Rai H, Kulla J, Lalith M. Genderwise morphometric database from adult atlas and axis. *JPAFMAT* [Internet]. 2008;8(2):25–9. Available from: <http://medind.nic.in/jbc/t08/i2/jbct08i2p25.pdf>
 36. Kandziora F, Schulze-Stahl N, Klostermann C, Schröder R. Screw placement in transoral atlantoaxial plate systems: an anatomical study. *J Neurosurg* [Internet]. 2001;95(1):80–7. Available from: https://www.researchgate.net/publication/11889212_Screw_placement_in_transoral_atlantoaxial_plate_systems_An_anatomical_study
 37. Patel N, Gupta D. A morphometric study of adult human atlas vertebrae in South Gujarat population, India. *Int J Res Med Sci* [Internet]. 2016;4380–6. Available from: <http://www.msjonline.org/index.php/ijrms/article/view/291>
 38. Ebraheim NA, Xu R, Ahmad M, Heck B. The Quantitative Anatomy of the Vertebral Artery Groove of the Atlas and Its Relation to the Posterior Atlantoaxial Approach. *Spine (Phila Pa 1976)* [Internet]. 1998 Feb;23(3):320–3. Available from: <https://insights.ovid.com/crossref?an=00007632-199802010-00007>