

Study on Dangerous Acupuncture Needling Depth at Yamen (GV15) for Atlantoaxial Dislocation based on MRI and CT

Jun Zhou¹, Feng Yang², Chun-ke Dong³, Rui Quan¹, Ping Yi², Xiang-sheng Tang²,
Hao-ning Ma², Ming-sheng Tan^{2*},

¹Beijing University of Chinese Medicine Third Affiliated Hospital, Beijing, 100029, China

²Department of Spine Surgery, China-Japan Friendship Hospital, Beijing, 100029, China

³Beijing Traditional Chinese Medicine Hospital Affiliated to Capital Medical University, Beijing, 100010, China

ABSTRACT

Background: The depth of acupuncture at GV15 significantly changes with atlantoaxial dislocation (AAD). Magnetic resonance imaging (MRI) and computed tomography (CT) are the current methods for assessing acupuncture depth. However, the acupuncture depth in patients with AAD and the best evaluation method for acupuncture have not been thoroughly studied.

Objectives: Based on MRI and 3D CT imaging measurements, dangerous needling depths for perpendicular acupuncture and oblique acupuncture in patients with AAD and normal anatomy were obtained. The application value of MRI and 3D CT in evaluating acupuncture depth is discussed.

Methods: From January 2018 to December 2021, patients with AAD (120 patients) and control patients without AAD (124 patients) diagnosed and treated at the Upper Cervical Spine Research Center of the China-Japan Friendship Hospital were selected. All patients were enrolled. Both groups included patients with normal body types (BMI 18.5-23.9). The two groups of patients underwent plain cervical MRI scans and three-dimensional plain CT scans, and the dangerous needling depth of the perpendicular spur and the oblique spur were measured on sagittal images.

Results: No significant differences were observed between the two measurements (MRI and CT) ($P < 0.05$). The dangerous needling depths in the AAD group were as follows: male straight stab: 45.33 ± 5.17 mm, male oblique stab: 48.58 ± 4.41 mm, female straight thorn: 44.17 ± 7.80 mm, and female oblique thorn: 47.49 ± 7.32 mm. The dangerous needling depths for the control group were as follows: male straight thorn: 47.72 ± 5.06 mm, male oblique thorn: 42.69 ± 5.53 mm, female straight thorn: 44.63 ± 5.85 mm, and female oblique thorn: 39.88 ± 6.18 mm.

Conclusions: Acupuncture depth at the dumb point of the AAD changed significantly. The clinical acupuncture depth should not exceed this safe depth. Both CT and MRI can be used to assess dangerous needling depth at GV15.

Corresponding Author: zrtanms@163.com.

How to cite this article: Zhou J, Yang F, Dong C, Quan R, Yi P, Tang X, Ma H, Tan M. Study on Dangerous Acupuncture Needling Depth at Yamen (GV15) for Atlantoaxial Dislocation based on MRI and CT. Journal of Complementary Medicine Research, Vol. 13, No. 4, 2022 (pp. 60-64).

INTRODUCTION

Yamen (GV15) is the fifteenth acupoint of the Governor Vessel Meridian, which is the intersection point of the governor vessel and Yang Wei Channel. GV15 is a common acupoint for treating head pain, aphasia, and psychosis. GV15 is located in the second cervical spinous (C2) process, along the centre line of the back.¹ Atlantoaxial dislocation (AAD) is caused by a variety of factors and leads to the loss of a normal relationship and stability between the atlas and axis, causing a series of dysfunctions.¹ AAD is associated with changes in the atlantoaxial anatomical structure; therefore, the depth of conventional acupuncture is no longer applicable for patients with AAD. However, there is a lack of current studies focusing on the risk and depth of acupuncture under abnormal anatomical conditions. GV15 is anatomically close to the medulla oblongata, and preventing damage to the spinal cord in clinical acupuncture has become an urgent problem.³ The distance from the needle insertion point to the medulla oblongata or spinal cord is called the dangerous depth of acupuncture. Therefore, defining the dangerous needling depth at GV15 is important for the clinical safety of acupuncture.⁴ Magnetic resonance imaging (MRI) and computed tomography (CT) are the mainstream imaging methods for assessing dangerous needling depth. However, choosing the best imaging method is still a major clinical challenge. Therefore, this study aimed to determine the dangerous acupuncture needling depth in patients with AAD at GV15 and to compare the two imaging methods of MRI and CT to explore their application value in evaluating dangerous needling depth for acupuncture. This study has guiding significance for clinical acupuncture.

KEYWORDS:

GV15,
Atlantoaxial dislocation,
Computed tomography
Dangerous needling depth,
Perpendicular acupuncture,
Oblique acupuncture,
magnetic resonance
imaging.

ARTICLE HISTORY:

Received : Apr 25, 2022
Accepted : Jun 20, 2022
Published: Sep 14, 2022

DOI:

10.5455/jcmr.2022.13.04.12

MATERIALS AND METHODS

Normal information

A retrospective analysis of 244 patients diagnosed and treated at the Upper Cervical Research Center of the China-Japan Friendship Hospital from January 2018 to December 2021 was performed. The details of the AAD group are as follows: 120 patients including 54 males and 66 females aged 18-80 years with an average age of 50.47 ± 15.23 years. The details of the control group are as follows: 124 patients with normal anatomical structures (without fractures or dislocations) without AAD including 53 males and 71 females aged 20-81 years with an average age of 49.18 ± 15.31 years. (Table 1)

Inclusion Criteria

For both the AAD group and the control group, the BMI ($\text{BMI} = \text{weight}(\text{kg}) / \text{height}^2 (\text{m}^2)$) was calculated according to height and weight, and patients with a normal body type ($18.5 \leq \text{BMI} < 24$) were selected.

According to the diagnostic criteria for AAD, the AAD group met the following criteria: (1) clinical manifestations and imaging examinations consistent with AAD or instability; and (2) on imaging, an atlas-dens interval (ADI) > 5 mm or space available for the cord (SAC) ≤ 13 mm or the presence of atlantoaxial joint instability.²

The control group excluded AAD and other diseases that cause spinal anatomical malformations.

Acupoint Positioning

For both the AAD group and the control group, acupoint positioning was based on the 2009 World Health Organization Western Pacific Region standard acupuncture point locations. The insertion point was in the posterior region of the neck in the depression superior to the spinous process of the second cervical vertebra (C2) on the posterior median line.¹

Scanning Method

The cervical spine was imaged in the AAD group and the control group with a GE 1.5 T MRI and three-dimensional CT in the Department of Radiology of the China-Japan Friendship Hospital.

Imaging measurements

All MRI measurements were taken from the median sagittal T1-weighted (T1W) image. After three-dimensional CT reconstruction, the median sagittal image was selected. Under the abovementioned GV15 acupoint method, the localization was performed, and measurements were acquired according to clinical operation habits and practical feasibility. Figure 1

shows the following: (1) measuring the GV15 neck posterior body surface and the level of the atlantoaxial space midpoint dural outer edge distance (OA) and the perpendicular risk acupuncture depth; and (2) measuring the distance between the posterior margin of the neck of the dumb door to the posterior margin of the foramen magnum and the midpoint of the posterior border of the atlantoaxial arch (OB) and the oblique risk acupuncture depth. The measured data were then converted to the actual distance according to the image scale. (Figure 1)

Statistical Processing

Analysis was performed with SPSS 22.0 software. The measurement data are expressed as the mean \pm standard deviation ($\bar{x} \pm s$). Paired Student's t-tests were performed to compare MRI and CT measurements between the groups. Paired Student's t-tests were performed to compare the perpendicular risk acupuncture depth and oblique risk acupuncture depth between groups. The perpendicular risk acupuncture depth and oblique risk acupuncture depth were compared between groups with independent sample Student's t-tests. The count data were analysed with chi-square tests (χ^2 tests). The differences were considered statistically significant at $P < 0.05$.

RESULTS

No significant differences were observed in sex, BMI, and age between the AAD group and the control group ($P > 0.05$). No significant differences were observed in the perpendicular risk acupuncture depth and oblique risk acupuncture depth between MRI and CT ($P > 0.05$). In the AAD group, the perpendicular risk acupuncture depths of males and females were smaller than the oblique risk acupuncture depths ($P < 0.01$); No significant differences were observed between males and females in the perpendicular risk acupuncture depth and the oblique risk acupuncture depth ($P > 0.05$). In the control group, the perpendicular risk acupuncture depths of males and females were greater than the oblique risk acupuncture depths ($P < 0.01$). The perpendicular risk acupuncture depth and the oblique risk acupuncture depth of males were greater than those of females ($P < 0.01$). The perpendicular risk acupuncture depth of males in the AAD group was smaller than that in the control group ($P < 0.01$). No significant differences were observed in the perpendicular risk acupuncture depths of females between the AAD group and the control group ($P > 0.05$). The oblique risk acupuncture depths of males and females in the AAD group were greater than those in the control group ($P < 0.01$). (Table 2)

DISCUSSION

GV15 comes from the "The Yellow Emperor's Internal Canon of Medicine", which has been discussed by doctors of all ages and is an effective acupoint for treating meridian symptoms

Table 1: Comparison of the general data between the two groups

Index	AAD Group	Control Group	Statistical value	P-value
Case	120	124		
Sex (Male/Female)	54/66	53/71	$\chi^2 = 0.126$	0.722
BMI	21.59 ± 1.45	21.31 ± 1.64	$t = 1.413$	0.159
Average age	50.47 ± 9.63	49.58 ± 11.34	$t = 0.661$	0.510

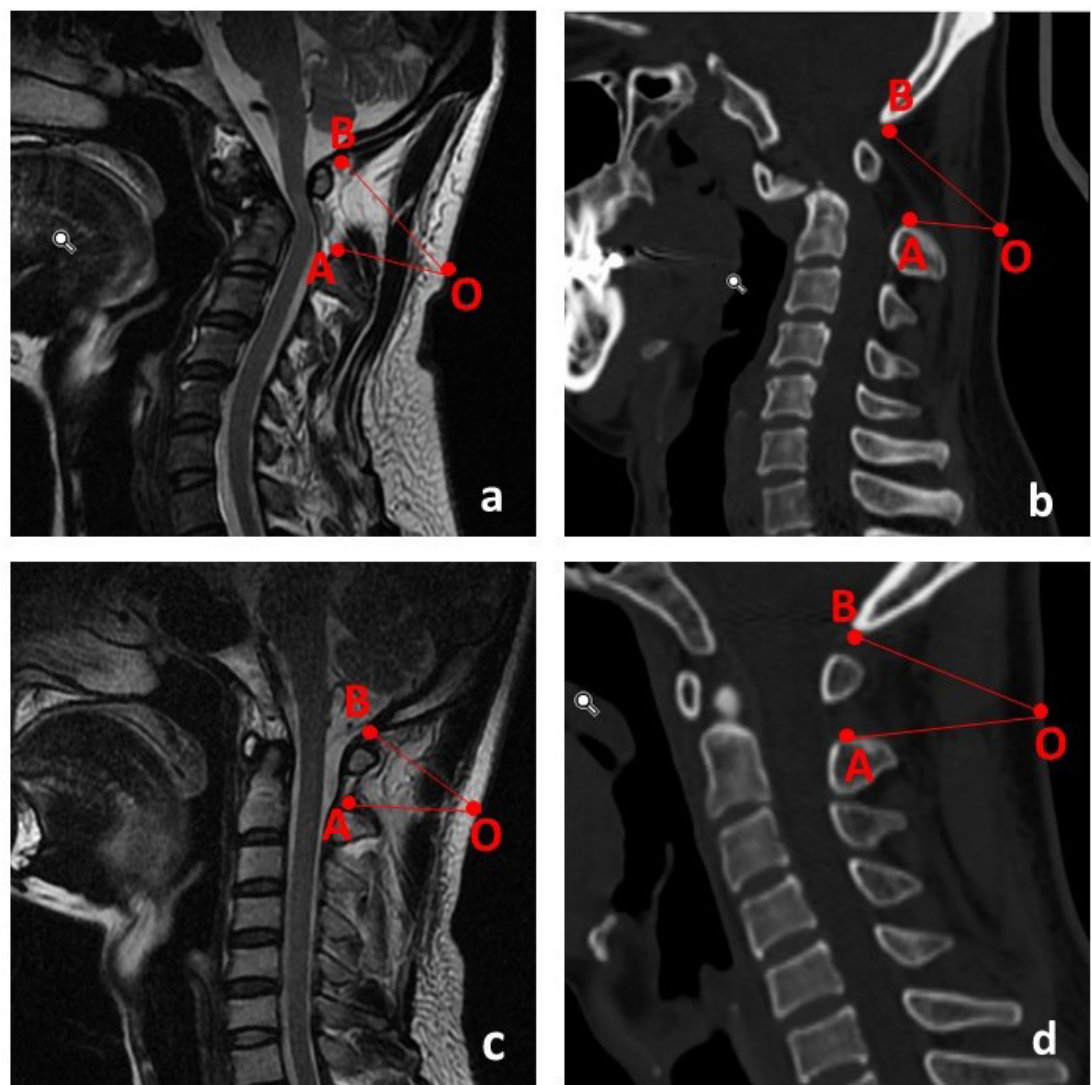


Fig. 1: GV15 measurement diagram (a AAD group MRI, b AAD group CT, c Control group MRI, d Control group CT)

Table 2: Comparing the dangerous needling depths between the two groups

Acupuncture direction	Sex	AAD Group				Control Group				
		MRI	CT	t-value	P-value	MRI	CT	t-value	P-value	
Perpendicular needling	Male 54	44.27 ± 4.15	43.96±3.60	0.415	0.679	Male 53	47.53±5.20 ³⁾	47.22±4.73 ³⁾	0.321	0.321
	Female 66	45.71 ± 5.43	45.14±5.16	0.618	0.538	Female 71	44.92±5.28 ⁴⁾	44.68±4.91 ⁴⁾	0.280	0.780
		1.597	1.475				2.733	2.892		
		0.113	0.143				0.007	0.005		
Oblique needling	Male 54	49.38 ±5.19 ¹⁾	48.72±6.08 ¹⁾	0.607	0.545	Male 53	44.46±3.49 ²⁾⁵⁾	44.84 ± 3.83 ²⁾⁵⁾	0.534	0.595
	Female 66	48.43±5.54 ¹⁾	47.91±6.33 ¹⁾	0.502	0.616	Female 71	42.51±3.67 ²⁾⁵⁾	42.30 ± 3.00 ²⁾⁵⁾	0.373	0.709
		0.962	0.711				2.992	4.138		
		0.338	0.478				0.003	0.000		

Annotation

- 1) In the AAD group, the oblique risk acupuncture depth was greater than the perpendicular risk acupuncture depth (P <0.01).
- 2) In the control group, the oblique risk acupuncture depth was smaller than the perpendicular risk acupuncture depth (P <0.01).
- 3) The perpendicular risk acupuncture depth of males in the AAD group was smaller than that in the control group (P <0.01).
- 4) No significant differences were observed in the perpendicular risk acupuncture depth of females between the AAD group and the control group (P>0.05).
- 5) The oblique risk acupuncture depths of males and females in the AAD group were greater than those in the control group (P <0.01).

and signs, aphasia, aphonia, and abnormal consciousness. A number of published studies have shown that GV15 should not be deeply punctured. If the acupuncture needle goes too deep, the medulla, also known as the centre of life, could be damaged. Therefore, the appropriate acupuncture depth needs to be carefully determined under different conditions to ensure safety.³

Studies have shown that during clinical acupuncture, the incidence of minor adverse events is 14/10 000, and the incidence of serious adverse events ranges from 0.05/10 000 to 0.55/10 000.⁵ When the acupuncture needling depth is too deep or when the angle is not correct, serious damage and even life-threatening events can occur, such as brain stem injury, spinal cord injury or subarachnoid haemorrhage.⁴

To ensure acupuncture safety at GV15, modern doctors have quantitatively studied the safe acupuncture range of GV15 based on anatomy and imaging. The perpendicular risk acupuncture depth and the oblique risk acupuncture depth were similar in this study.⁶ Zhou Deyu divided the body into thin, moderate, and short portions, and the dangerous acupuncture needling depth was obtained with CT measurements.⁶ Tang Juan compared different age groups to identify the dangerous acupuncture needling depth for different body types and clearly showed that no correlation existed between dangerous needling depth and age.⁷ Tang Zhusheng compared the results of MRI and cadaver specimens. The results of MRI were significantly different from those of cadaver specimens. Moreover, tissue damage, expansion and contraction were observed during the processing of cadaver specimens, and MRI measurements were superior to cadaver measurements.⁸

AAD is caused by trauma, congenital malformation, degeneration and other factors; the atlas and axis joints lose their normal relationship and stability, and pathologically, joint dysfunction, spinal cord injury and nerve compression occurs. The main clinical manifestations are occipital neck pain, limited neck activity, and limb weakness, and the condition may be accompanied by symptoms of vertebral artery insufficiency, such as dizziness or tinnitus. Severe cases can lead to paralysis and can even be life threatening.²

GV15 can achieve a certain effect in improving the dysfunction caused by AAD (such as neck pain and limited neck mobility).⁹ The abnormal anatomical structure of the atlantoaxial axis in AAD patients changes the structure of the normal dumb gates; however, the anatomical structure of the acupoints is not critical since the core is normal gas, and the changes to the core and acupuncture should change with the occurrence of disease.^{10,11} Therefore, determining the dangerous acupuncture needling depth for AAD disease at GV15 is particularly important. The use of a standard acupuncture depth is an important method to prevent adverse events caused by acupuncture.¹²

The local anatomical structure of the acupoints will change significantly, and the dangerous needling depth will also change significantly. For patients with anatomic abnormalities, acupuncture may not be performed at the same depth that would apply for patients with normal anatomy. The needling depth should be re-evaluated.

Clinical acupuncture cannot exceed the dangerous needling depth, but mechanical acupuncture cannot be relied on.

The scope of treatment must account for the patient's age, sex, body type and other aspects of impact, as well as the patient's position, needle selection, needle retention time and other factors.¹³ Studies have clearly demonstrated that the safe acupuncture depth is related to body size,^{3,4} but because AAD patients are rare, no relevant research exists. Through imaging studies, it is clear that a certain range of safe angles exist for acupuncture, which was discussed in detail in another article.¹⁴

This study on the dangerous acupuncture needling depth for AAD at GV15 was based on MRI and CT imaging measurements and used statistical methods to analyse patients with normal body types ($18.5 \leq \text{BMI} < 24$) in the AAD group and the control group. The results are summarized as follows: (1) AAD group and the control group: The MRI and CT dangerous needling depth lines were analysed with a paired t-test, and no significant differences were observed in the MRI and CT findings between all patients ($P > 0.05$). (2) MRI and CT imaging measurements: No differences were observed in the depth of GV15 acupuncture between MRI and CT, which may be because the risks at GV15 occur when the dura or medulla is injured, and the points are taken with the pivotal and atlas points as markers. Therefore, the CT results are the same as the MRI results. There were no significant differences. (3) The dangerous acupuncture needling depth at GV15 for AAD patients is greater than the perpendicular risk acupuncture depth. The dangerous needling depth in control patients is smaller than the perpendicular risk acupuncture depth, which may be because AAD mostly features anterior dislocations, and a posterior dislocation of the atlas is beyond the odontoid process;¹⁵ thus, the posterior arch and spinal cord of the atlas are more commonly located anatomically forward; therefore, the perpendicular risk acupuncture depth is greater than the oblique risk acupuncture depth. Under normal anatomical conditions, due to the physiological curvature of the human cervical vertebra (C2 is bent backwards), the oblique risk acupuncture depth is smaller than the perpendicular risk acupuncture depth. (4) No significant difference was observed in the risk of acupuncture needling depth at GV15 between male and female AAD patients. In patients with normal anatomy, the risk needling depth of perpendicular acupuncture and oblique acupuncture for males were greater than those for females, which may be because AAD patients have abnormalities in the atlantoaxial structure, which are mostly caused by abnormal development, resulting in no significant difference in the dangerous needling depth between males and females for both straight stabs and oblique stabs. The dangerous acupuncture needling depths in patients with normal anatomy are the same as those reported in other studies.^{3,6-8} (5) The risk of perpendicular acupuncture in male AAD patients is lower than that in patients with normal anatomy (which is due to the same reason as above: developmental abnormalities). The oblique risk acupuncture depth in AAD patients (male and female) is greater than that in patients with normal anatomy (male and female) (which is due to the same reason: the forward movement of the posterior arch of the atlas). No significant differences were observed in the perpendicular risk acupuncture depth between female AAD patients and female patients with normal anatomy, which may be because of the following reasons: female patients with AAD and those with normal

anatomy are at a decreased risk compared with males, but the female cervical skeleton is slightly smaller than the male cervical skeleton. However, ensuring functional needs is still important, so the risk reduction of straight thorns for female patients with AAD is not obvious, and significant differences cannot be observed.

CONCLUSION

Clinical risk acupuncture assessments are particularly important for clinical acupuncture safety. MRI and CT can be used when the bones serve as markers. Three-dimensional CT imaging of non-supervised acupoints has certain advantages over MRI. MRI is superior to CT when the acupoints are evaluated in other ways, especially in regard to soft tissue levels. Both imaging modalities can be used to determine the dangerous needling depth for GV15.

In the AAD state, the risk of acupuncture at GV15 is significantly changed, and the clinical acupuncture depth should not exceed the dangerous needling depth. Moreover, combining specific situations and paying close attention to vital signs is important in preventing adverse events from occurring.

Declaration of conflicting interests

The authors declare no potential conflicts of interest with respect to the research, authorship, and/or publication of this article.

Funding: This work was supported by the National Natural Science Foundation of China (grant no. 81873141, 82074218); Application Research Project of Capital Clinical Characteristic of Beijing Science and Technology Plan (grant no. Z16110000516009).

Ethical approval of studies and informed consent: The trial was approved by the Ethics Committee of the China-Japan Friendship Hospital, Beijing, China (Approval number: zryhy-21-21-01-02).

REFERENCES

1. World health organization western pacific region, WHO standard acupuncture point locations in the western pacific region ,2009
2. Tan MS. Upper Cervical Surgery. Beijing: People's Medical Publishing House, 2010: 334.
3. Park S J , Jin M , Joo J C , et al. Assessment of Factors Associated with the Safety Depth of GV15 Yamen -Factors Associated with the Safety Depth of GV15-J.. Journal of Pharmacopuncture, 2014, 17(1):70-3.
4. Chou PC, Chu HY, Lin JG. Safe needling depth of acupuncture pointsJ.. Journal of Alternative and Complementary Medicine,2011,17(3):199-206
5. Lu W, Rosenthal D S. Recent Advances in Oncology Acupuncture and Safety Considerations in PracticeJ.. Current Treatment Options in Oncology, 2010, 11 (3-4) : 141.
6. Zhou DY, Si YC, Yuan CH, Zhou J. Yamen CT measurement study on the relationship between safety acupuncture depth and neck circumference. Zhongguo Zhen Jiu, 1995, 15(3): 41-42, 60.
7. Tang J, Wang XL, Liao XF, Ouyang PF. Research on application of MRI in measuring acupuncture dangerous depth at Yamen (GV 15) and Fengfu (GV 16). Chongqing Yixue, 2014, 43(11): 1317-1319.
8. Tang ZS, Yan X, Cong SY, et al. Magnetic resonance imaging and corpse control study of acupuncture at a safe depth in Fengfu and Yamen acupointsJ.. Journal of Yunnan College of Traditional Chinese Medicine, 2013, 5:28-29.
9. Zhou J, Zhao FY, Li WH, et al. Safety depth of acupuncture at Yamen (GV 15) in patients with atlantoaxial dislocation. Zhongguo Zhen Jiu, 2019,39(06):619-622.
10. Shen F. Explanation on acupoint intention. Zhongguo Zhen Jiu, 2017, 37(6): 621-623.
11. Zhao JS. Analysis on the acupoint conception. Zhongguo Zhen Jiu, 2017, 37(2): 149-152.
12. Wang C, Liu BY, Liu Y, He LY, Li HJ, Liu J. Analysis on the concepts related to adverse events and adverse reactions of acupuncture. Zhongguo Zhen Jiu, 2018, 38(1): 87-90.
13. Ma JJ, Meng XW, Zheng YC, Lin WD, Wang Y, Guo Y, Liu YX. Preliminary study on the essential factors for security needle of acupoints. Sichuan Zhongyi, 2017, 35(12): 15-17.
14. Zhou J, Zhao FY, Li WH, et al. Study on the angle of needling Yamen (GV 15) in atlanto-axial dislocation patients. J Acupunct Tuina Sci, 2019, 17(3): 141-146
15. Song R, Fan D, Wu H, et al. Management of Unusual Atlantoaxial Dislocation.J.. Spine, 2017, 42(8):573.