



## Assessment of Use of Periodontal Dressing After Scalpel Frenectomy And Frenotomy - A Retrospective Study

Jagadish Rajkumar<sup>1</sup>, Balaji Ganesh S<sup>2\*</sup>, SS Raj<sup>3</sup>

<sup>1</sup>Saveetha Dental College and Hospitals, Saveetha Institute of Medical and Technical Sciences, Saveetha University, Chennai - 600077, India.  
Email: [151601004.sdc@saveetha.com](mailto:151601004.sdc@saveetha.com)

<sup>2</sup>Senior lecturer, Department of Periodontics, Saveetha Dental College and Hospitals, Saveetha Institute of Medical and Technical Sciences, Saveetha University, Chennai - 600077, India.  
Email id: [balajiganeshs.sdc@saveetha.com](mailto:balajiganeshs.sdc@saveetha.com)

<sup>3</sup>Reader, Department of Public Health Dentistry, Saveetha Dental College and Hospitals, Saveetha Institute of Medical and Technical Sciences, Saveetha University, Chennai - 600077, India.  
Email: [samuelrajs.sdc@saveetha.com](mailto:samuelrajs.sdc@saveetha.com)

### ABSTRACT

The aberrant frenum attachment can be treated by frenectomy and frenotomy. There are various treatment options like using scalpel, electrosurgery and lasers. After these procedures a periodontal dressing is usually advised. It prevents or minimizes the post operative infections, hemorrhage and allows the healing process to proceed without any disturbance. The present study focuses on the preferences of the dental surgeon to place periodontal dressing after scalpel frenectomy and frenotomy procedure. The sample size was 71 patients. 73.2% were patients underwent frenectomy and 27% patients underwent frenotomy, in 73% of cases the dental surgeon preferred periodontal dressing (coe-pak) after frenotomy and in 82% of cases the dental surgeon preferred a periodontal dressing (coe-pak) frenectomy. The most number of female patients underwent frenectomy (43.66%) and frenotomy (16.90%) procedures when compared to male patients. p value=0.78 (> 0.05), hence the association was found to be statistically not significant. Within the limits of our study, we conclude by saying that most of the dental surgeons prefer using periodontal dressing (coe-pak) after scalpel frenectomy and frenotomy procedure.

### ARTICLE HISTORY

Received October 15, 2020  
Accepted November 20, 2020  
Published December 09, 2020

### KEYWORDS


Frenectomy, Frenotomy,  
Infection control,  
Periodontal dressing.


### INTRODUCTION

The frenum in simple terms can be defined as a mucous membrane fold which contains mucous and connective tissue fibres that attach the lip to the alveolar mucosa, gingiva and the underlying periosteum [1]. The abnormal labial frenum is usually detected by applying tension over the frenum to see the movement of the papillary tip or the blanch which is produced due to the ischemia in the region [2]. The frenum is characterized as unusual when it is usually wide or when there is no

apparent zone of attached gingiva along the midline or the interdental papilla shift is noted when the frenum is extended [3]. The frenal attachments on the labial aspect have been classified as mucosal, gingival, papillary and papilla penetrating [4]. The most common of all frenum abnormality is the atypical frenal attachment causing midline diastema [5].

A flattened type of papilla along with the frenum closely attached to the margin of the gingiva can lead to development of gingival recession and

\* **Contact:** Balaji Ganesh S,  Senior lecturer, Department of Periodontics, Saveetha Dental College and Hospitals, Saveetha Institute of Medical and Technical Sciences, Saveetha University, Chennai - 600077, India.

 [balajiganeshs.sdc@saveetha.com](mailto:balajiganeshs.sdc@saveetha.com)

2020 The Authors. This is an open access article under the terms of the Creative Commons Attribution Non-Commercial Share Alike 4.0 (<https://creativecommons.org/licenses/by-nc-sa/4.0/>).

makes it difficult to maintain oral health. The abnormal labial frenum with inadequately available attached gingiva and a shallow vestibule is also seen [6,7]. These conditions are treated by frenectomy or complete removal of the frenum and by frenotomy which is the incision and repositioning of the frenal attachment [8]. In most cases after the surgical procedures are completed, the surgical site is covered by a periodontal dressing [9,10]. They are not involved in curing the trauma but they minimize the chances of postoperative infection, hemorrhage, prevents surface trauma to the mucosa under mastication and protects the surface from food and other disturbances like tongue [11]. They aid in the healing process to continue undisturbed [12-16].

Previously our team had conducted various studies on treatment modalities for periodontal diseases and periodontal procedures, studies correlating various diseases and factors related to periodontal diseases and in-vitro & radiological studies over the past 5 years [17-32][17,21-23,27-29,31,33-40]. Now we are focusing on the various other conditions that will guide us and give a deeper understanding in managing periodontal conditions. Our present study focuses on the preference of the dental surgeon to place periodontal dressing after a scalpel frenectomy and frenotomy procedure.

## MATERIALS AND METHODS

### Study Setting

This is a retrospective study which involved patients who had undergone surgical frenectomy and frenotomy. It was done as a university setting study, which included patients who have undergone treatment at Saveetha Dental College and Hospital, Chennai in between the time period of June 2019- April 2020. The Institutional Ethical Committee gave the ethical approval for this study (ethical approval number - SDC/ SIHEC/ 2020/ DIASDATA/ 0619-0320).

### Data Collection & Tabulation

The sample size of the present study is 71 patients. Inclusion criteria were both male and female patients who had high labial frenum attachment and those who had undergone frenectomy and frenotomy by scalpel method. Exclusion criteria was incomplete data in the case sheets and patients who had undergone frenectomy and frenotomy by laser and electrocautery method. The detailed case sheets of all the patients were analyzed with respect to parameters such as gender, type of procedure which includes frenectomy and frenotomy and placement of the periodontal dressing (coe-pak). The data was manually retrieved and tabulated in Excel and sorted. Intraoral photographs were also used to verify the data.

### Statistical Analysis

After further verification of data by an external reviewer, it was imported to the SPSS software by IBM in order to get a statistical report. Percentages, mean, frequency of certain parameters were employed in the analysis. Chi-square test was used to detect the association between the frenectomy and frenotomy procedures with the gender of patients involved in the study. p value less than 0.05 was considered to be statistically significant.

## RESULTS AND DISCUSSION

The data collected from the patient management software were tabulated and the descriptive statistics were obtained for a total of 71 patients, who were included in the retrospective study. The female population(60.56%) was greater than the male population(39.44%) as shown in figure 1. 73.2% were patients who underwent frenectomy and 27% patients underwent frenotomy as shown in figure 2. In 74% of patients, the dental surgeons preferred the placement of periodontal dressing (coe-pak) after frenotomy and 26% did not get the periodontal dressing as shown in figure 3.

Under the category of frenectomy, 83% patients received periodontal dressing (coe-pak) and 17% did not get any periodontal dressing as shown in figure 4. The association between the frenectomy and frenotomy procedures with the gender of patients was analysed. The most number of female patients underwent frenectomy (43.66%) and frenotomy (16.90%) procedures followed by the males who underwent frenectomy (29.58%) and frenotomy (9.68%) procedures, However, the p value was 0.78 ( $> 0.05$ ) which shows that there is no statistically significant association which is shown in figure 5.

Our study is first of its kind, as there are no studies in the literature that established a dental surgeons preference of using periodontal dressing following frenectomy and frenotomy procedures by scalpel. By the results of our study we observe that periodontal dressing is preferred after conventional scalpel frenectomy and frenotomy procedures by most of the dental surgeons. There are no related studies to this context. Miller et al advised the use of periodontal dressing following any periodontal surgical procedure, because the periodontal dressing may enhance the healing and protects the surgical site from any kind of foreign body disturbances. This is in acceptance with our study [41].

The types of periodontal dressing includes those which has zinc oxide and eugenol, zinc oxide without addition of eugenol and those which has neither zinc oxide nor eugenol material ([12-16]). Coe-Pak was commonly used by the dental surgeons in the present study. Coe-Pak contains

zinc oxide without addition of eugenol material. It is available in the form of a two tube paste system. One tube contains zinc oxide, a gum, oil and lorchidol material. The other tube contains colophony resin, coconut fatty acids and chlorothymol material. The contents of the two tubes are placed in a glass slab in equal amounts and mixed immediately using a spatula. Then, after an even mix the dressing material is carried and placed on the surgical site of frenectomy or frenotomy. ([12–16]).

During the development stage, the absence of the apical migration of the maxillary labial frenum has been implicated as the reason for the development of the midline diastema. There is spacing seen in between the maxillary central incisors. Midline diastema is usually associated with high frenal attachment of papillary type and the papillary penetrating type [4,42]). In the present study, more number of female patients underwent frenectomy and frenotomy procedures by using the scalpel method when compared to males. This is in acceptance with the study done by jindal et al, according to which the gender related variations in labial frenum attachments were found to be more prevalent among female patients when compared to male patients [43]. Few limitations of the study design could be that it is a single center study with less sample size, similar ethnicity and geographic location. To improve the significance of the study, it should be done extensively with a large amount of sample size, so that the results are even more reliable.

## CONCLUSION

We conclude by saying that most of the dental surgeons prefer placing periodontal dressing (coepak) after frenectomy and frenotomy procedure by using conventional scalpel method. Periodontal dressing use is really beneficial as it protects the surgical site from mechanical trauma and enhances healing. Periodontal dressing also helps in prevention of post-operative infection.

## AUTHOR CONTRIBUTION

Jagadish, Dr. Balaji Ganesh S and Dr. Samuel contributed to the design and implementation of the research, to the analysis of the results and to the writing of the manuscript.

## CONFLICT OF INTEREST

The authors declare no potential conflict of interest.

## REFERENCES

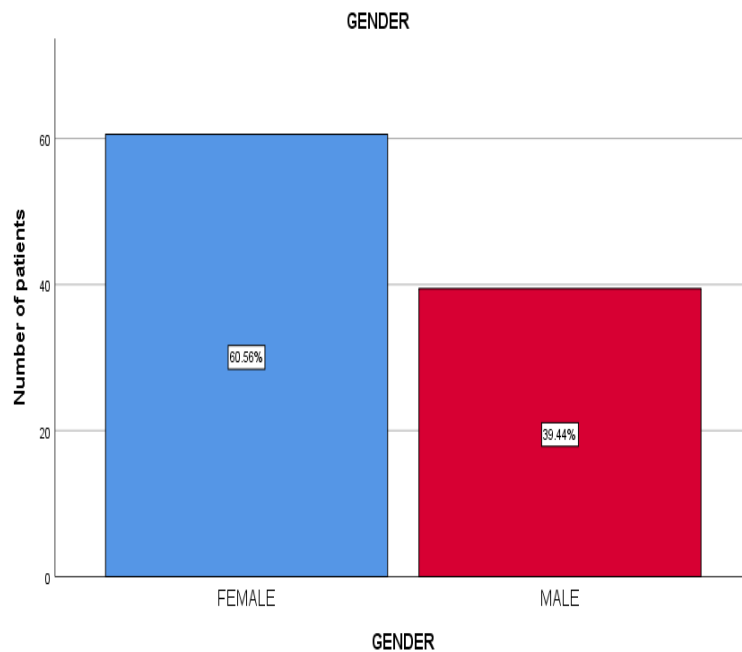
1. Huang W-J, Creath CJ. The midline diastema: a review of its etiology and treatment. *Pediatr Dent*. 1995;17:171–171.
2. Punj A. Management of an Aberrant

- Mandibular Buccal Frenum - A Case Report [Internet]. Vol. 3, *Open Access Journal of Dental Sciences*. 2018. Available from: <http://dx.doi.org/10.23880/oajds-16000158>
3. Agrawal DP, Agrawal P, Dept. Of Periodontics, Professor A, Bharati Vidyapeeth Deemed University Dental College and Hospital, Pune, et al. Treatment of an Unusual Case of Thick, Broad Frenum – A Case Report [Internet]. Vol. 3, *Paripex - Indian Journal Of Research*. 2012. p. 1–2. Available from: <http://dx.doi.org/10.15373/22501991/july2014/59>
4. Pandey S. Laser Frenectomy of Papilla Penetrating Frenum - A Case Report [Internet]. Vol. 2, *Acta Scientific Dental Sciencs*. 2019. p. 22–4. Available from: <http://dx.doi.org/10.31080/asds.2019.03.0668>
5. Schwartz AB. EFFECT OF GROWTH AND DEVELOPMENT ON ABNORMAL LABIAL FRENUM [Internet]. Vol. 71, *Archives of Pediatrics & Adolescent Medicine*. 1946. p. 248. Available from: <http://dx.doi.org/10.1001/archpedi.1946.0202060041003>
6. Mirko P, Miroslav S, Lubor M. Significance of the Labial Frenum Attachment in Periodontal Disease in Man. Part 1. Classification and Epidemiology of the Labial Frenum Attachment [Internet]. Vol. 45, *Journal of Periodontology*. 1974. p. 891–4. Available from: <http://dx.doi.org/10.1902/jop.1974.45.12.891>
7. Kikuta S, Ibaragi S. Anatomy and Variations of the Lingual Frenum and Sublingual Surface [Internet]. *Anatomical Variations in Clinical Dentistry*. 2019. p. 157–66. Available from: [http://dx.doi.org/10.1007/978-3-319-97961-8\\_15](http://dx.doi.org/10.1007/978-3-319-97961-8_15)
8. Schwartz AB. THE RATIONAL TREATMENT OF ABNORMAL LABIAL FRENUM [Internet]. Vol. 52, *Archives of Pediatrics & Adolescent Medicine*. 1936. p. 1061. Available from: <http://dx.doi.org/10.1001/archpedi.1936.04140050017002>
9. Kumar MBV, Narayanan V, Jalaluddin M, Almalki SA, Dey SM, Sathe S. Assessment of Clinical Efficacy of Different Periodontal Dressing Materials on Wound Healing: A Comparative Study. *J Contemp Dent Pract*. 2019 Aug 1;20(8):896–900.
10. Dibart S, Karima M. Labial Frenectomy Alone or in Combination with a Free Gingival Autograft [Internet]. *Practical Periodontal Plastic Surgery*. 2017. p. 73–5. Available from: <http://dx.doi.org/10.1002/9781119014775.ch13>

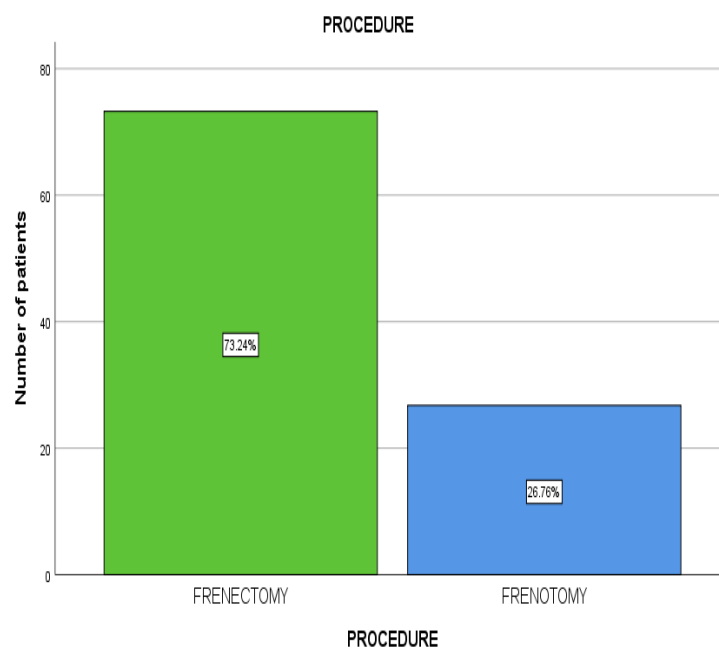
11. Pihlstrom BL, Thorn HL, Folke LEA. The Effect of Periodontal Dressing on Supragingival Microorganisms [Internet]. Vol. 48, Journal of Periodontology. 1977. p. 440–5. Available from: <http://dx.doi.org/10.1902/jop.1977.48.8.440>
12. Asboe-Jørgensen V, Attström R, Lang NP, Løe H. Effect of a Chlorhexidine Dressing on the Healing After Periodontal Surgery [Internet]. Vol. 45, Journal of Periodontology. 1974. p. 13–7. Available from: <http://dx.doi.org/10.1902/jop.1974.45.1.13>
13. Kale DT, Kale T, Reader & Guide Dept. Of Periodontology MGV'S KBH Dental College & Hospital, Maharashtra N, India, Dani N, et al. Periodontal Dressing [Internet]. Vol. 13, IOSR Journal of Dental and Medical Sciences. 2014. p. 94–8. Available from: <http://dx.doi.org/10.9790/0853-13349498>
14. Dahiya R, Blaggana A, Panwar V, Kumar S, Kathuria A, Malik S. Clinical and histological comparison of platelet-rich fibrin versus non-eugenol periodontal dressing in the treatment of gingival hyperpigmentation. J Indian Soc Periodontol. 2019 Jul;23(4):345–50.
15. Genovesi AM, Ricci M, Marchisio O, Covani U. Periodontal dressing may influence the clinical outcome of non-surgical periodontal treatment: a split-mouth study [Internet]. Vol. 10, International Journal of Dental Hygiene. 2012. p. 284–9. Available from: <http://dx.doi.org/10.1111/j.1601-5037.2010.00493.x>
16. Ramamurthy J, Mg V. COMPARISON OF EFFECT OF HIORA MOUTHWASH VERSUS CHLORHEXIDINE MOUTHWASH IN GINGIVITIS PATIENTS: A CLINICAL TRIAL [Internet]. Vol. 11, Asian Journal of Pharmaceutical and Clinical Research. 2018. p. 84. Available from: <http://dx.doi.org/10.22159/ajpcr.2018.v11i7.24783>
17. Robert R, Justin Raj C, Krishnan S, Jerome Das S. Growth, theoretical and optical studies on potassium dihydrogen phosphate (KDP) single crystals by modified Sankaranarayanan–Ramasamy (mSR) method [Internet]. Vol. 405, Physica B: Condensed Matter. 2010. p. 20–4. Available from: <http://dx.doi.org/10.1016/j.physb.2009.08.015>
18. Sahu D, Kannan GM, Vijayaraghavan R. Size-dependent effect of zinc oxide on toxicity and inflammatory potential of human monocytes. J Toxicol Environ Health A. 2014;77(4):177–91.
19. Suresh P, Marimuthu K, Ranganathan S, Rajmohan T. Optimization of machining parameters in turning of Al-SiC-Gr hybrid metal matrix composites using grey-fuzzy algorithm [Internet]. Vol. 24, Transactions of Nonferrous Metals Society of China. 2014. p. 2805–14. Available from: [http://dx.doi.org/10.1016/s1003-6326\(14\)63412-9](http://dx.doi.org/10.1016/s1003-6326(14)63412-9)
20. DeSouza SI, Rashmi MR, Vasanthi AP, Joseph SM, Rodrigues R. Mobile phones: the next step towards healthcare delivery in rural India? PLoS One. 2014 Aug 18;9(8):e104895.
21. Sekhar CH, Narayanan V, Baig MF. Role of antimicrobials in third molar surgery: prospective, double blind, randomized, placebo-controlled clinical study. Br J Oral Maxillofac Surg. 2001 Apr;39(2):134–7.
22. Chellaswamy C, Ramesh R. Parameter extraction of solar cell models based on adaptive differential evolution algorithm [Internet]. Vol. 97, Renewable Energy. 2016. p. 823–37. Available from: <http://dx.doi.org/10.1016/j.renene.2016.06.024>
23. Danda AK, Muthusekhar MR, Narayanan V, Baig MF, Siddareddi A. Open versus closed treatment of unilateral subcondylar and condylar neck fractures: a prospective, randomized clinical study. J Oral Maxillofac Surg. 2010 Jun;68(6):1238–41.
24. Samuel MS, Bhattacharya J, Raj S, Santhanam N, Singh H, Pradeep Singh ND. Efficient removal of Chromium(VI) from aqueous solution using chitosan grafted graphene oxide (CS-GO) nanocomposite. Int J Biol Macromol. 2019 Jan;121:285–92.
25. Lakshmanan A, Bhaskar RS, Thomas PC, Satheesh Kumar R, Siva Kumar V, Jose MT. A red phosphor for nUV LED based on (Y,Gd)BO<sub>3</sub>:Eu<sup>3+</sup> [Internet]. Vol. 64, Materials Letters. 2010. p. 1809–12. Available from: <http://dx.doi.org/10.1016/j.matlet.2010.05.034>
26. Venu H, Subramani L, Dhana Raju V. Emission reduction in a DI diesel engine using exhaust gas recirculation (EGR) of palm biodiesel blended with TiO<sub>2</sub> nano additives [Internet]. Vol. 140, Renewable Energy. 2019. p. 245–63. Available from: <http://dx.doi.org/10.1016/j.renene.2019.03.078>
27. Manimaran G, Pradeep kumar M, Venkatasamy R. Influence of cryogenic cooling on surface grinding of stainless steel 316 [Internet]. Vol. 59, Cryogenics. 2014. p. 76–83. Available from: <http://dx.doi.org/10.1016/j.cryogenics.2013.11.005>
28. Neelakantan P, Varughese AA, Sharma S,

- Subbarao CV, Zehnder M, De-Deus G. Continuous chelation irrigation improves the adhesion of epoxy resin-based root canal sealer to root dentine. *Int Endod J*. 2012 Dec;45(12):1097–102.
29. Babu MN, Naresh Babu M, Muthukrishnan N. Investigation on Surface Roughness in Abrasive Water-Jet Machining by the Response Surface Method [Internet]. Vol. 29, *Materials and Manufacturing Processes*. 2014. p. 1422–8. Available from: <http://dx.doi.org/10.1080/10426914.2014.952020>
  30. Panda S, Doraiswamy J, Malaiappan S, Varghese SS, Del Fabbro M. Additive effect of autologous platelet concentrates in treatment of intrabony defects: a systematic review and meta-analysis. *J Investig Clin Dent*. 2016 Feb;7(1):13–26.
  31. Adalarasan R, Santhanakumar M, Rajmohan M. Optimization of laser cutting parameters for Al6061/SiCp/Al2O3 composite using grey based response surface methodology (GRSM) [Internet]. Vol. 73, *Measurement*. 2015. p. 596–606. Available from: <http://dx.doi.org/10.1016/j.measurement.2015.06.003>
  32. Rajeshkumar S, Kumar SV, Ramaiah A, Agarwal H, Lakshmi T, Roopan SM. Biosynthesis of zinc oxide nanoparticles using *Mangifera indica* leaves and evaluation of their antioxidant and cytotoxic properties in lung cancer (A549) cells. *Enzyme Microb Technol*. 2018 Oct;117:91–5.
  33. Sahu D, Kannan GM, Vijayaraghavan R. Size-dependent effect of zinc oxide on toxicity and inflammatory potential of human monocytes. *J Toxicol Environ Health A*. 2014;77(4):177–91.
  34. Suresh P, Marimuthu K, Ranganathan S, Rajmohan T. Optimization of machining parameters in turning of Al-SiC-Gr hybrid metal matrix composites using grey-fuzzy algorithm [Internet]. Vol. 24, *Transactions of Nonferrous Metals Society of China*. 2014. p. 2805–14. Available from: [http://dx.doi.org/10.1016/s1003-6326\(14\)63412-9](http://dx.doi.org/10.1016/s1003-6326(14)63412-9)
  35. DeSouza SI, Rashmi MR, Vasanthi AP, Joseph SM, Rodrigues R. Mobile phones: the next step towards healthcare delivery in rural India? *PLoS One*. 2014 Aug 18;9(8):e104895.
  36. Samuel MS, Bhattacharya J, Raj S, Santhanam N, Singh H, Pradeep Singh ND. Efficient removal of Chromium(VI) from aqueous solution using chitosan grafted graphene oxide (CS-GO) nanocomposite. *Int J Biol Macromol*. 2019 Jan;121:285–92.
  37. Lakshmanan A, Bhaskar RS, Thomas PC, Satheesh Kumar R, Siva Kumar V, Jose MT. A red phosphor for nUV LED based on (Y,Gd)BO3:Eu3 [Internet]. Vol. 64, *Materials Letters*. 2010. p. 1809–12. Available from: <http://dx.doi.org/10.1016/j.matlet.2010.05.034>
  38. Venu H, Subramani L, Dhana Raju V. Emission reduction in a DI diesel engine using exhaust gas recirculation (EGR) of palm biodiesel blended with TiO2 nano additives [Internet]. Vol. 140, *Renewable Energy*. 2019. p. 245–63. Available from: <http://dx.doi.org/10.1016/j.renene.2019.03.078>
  39. Panda S, Doraiswamy J, Malaiappan S, Varghese SS, Del Fabbro M. Additive effect of autologous platelet concentrates in treatment of intrabony defects: a systematic review and meta-analysis. *J Investig Clin Dent*. 2016 Feb;7(1):13–26.
  40. Rajeshkumar S, Kumar SV, Ramaiah A, Agarwal H, Lakshmi T, Roopan SM. Biosynthesis of zinc oxide nanoparticles using *Mangifera indica* leaves and evaluation of their antioxidant and cytotoxic properties in lung cancer (A549) cells. *Enzyme Microb Technol*. 2018 Oct;117:91–5.
  41. Miller PD Jr. The frenectomy combined with a laterally positioned pedicle graft. Functional and esthetic considerations. *J Periodontol*. 1985 Feb;56(2):102–6.
  42. Krusteva S. CORRECTING LABIAL THICK AND HIGH ATTACHED FRENUM (CLINICAL OBSERVATION) [Internet]. Vols. 18, 4, *Journal of IMAB - Annual Proceeding (Scientific Papers)*. 2012. p. 263–5. Available from: <http://dx.doi.org/10.5272/jimab.2012184.263>
  43. Jindal V, Kaur R, Goel A, Mahajan A, Mahajan N, Mahajan A. Variations in the frenal morphology in the diverse population: A clinical study. *J Indian Soc Periodontol*. 2016 May;20(3):320–3.

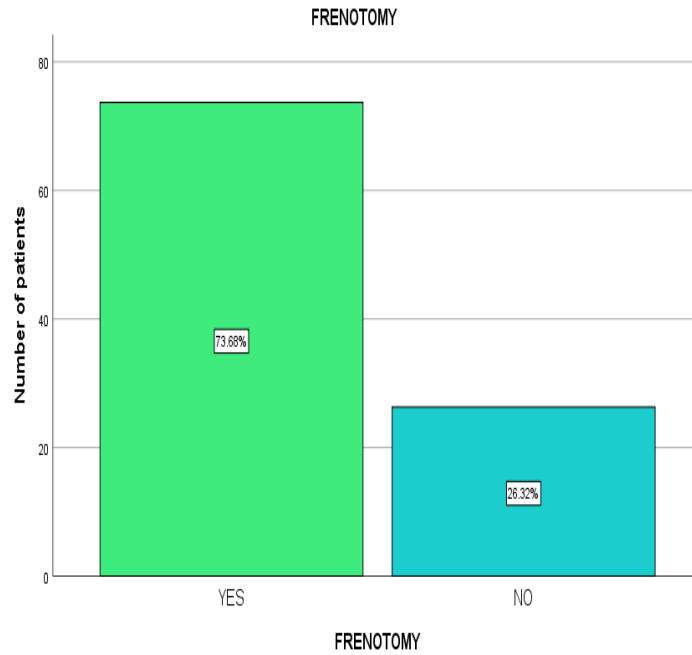
## BAR GRAPHS



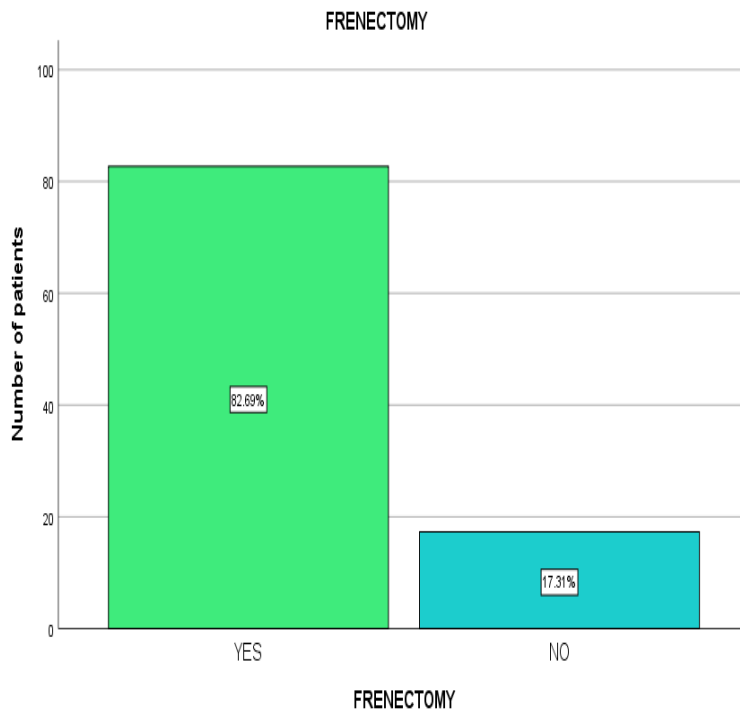
**Figure 1:** This graph represents the frequency of the gender distribution involved in the study. X axis denotes the gender and Y axis denotes the number of the patients involved in the study. The female population (60.5%) was more than the male population (39.4%).



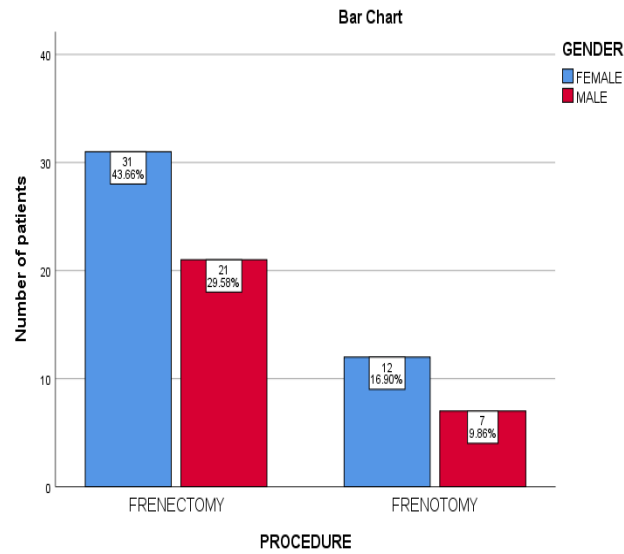
**Figure 2:** This graph represents the frequency of the frenectomy and frenotomy procedures distribution involved in the study. X axis denotes the procedures involved in the study and Y axis denotes the number of the patients involved in the study. The frenectomy procedure (73.24%) was performed more when compared to frenotomy procedure (26.76%).



**Figure 3:** This graph represents the frequency of the periodontal dressing placed in frenotomy cases. X axis denotes the preference to periodontal dressing after frenotomy and Y axis denotes the number of the patients involved in the study. The preference for periodontal dressing in frenotomy cases was 73.6%



**Figure 4:** This graph represents the frequency of the periodontal dressing placed in frenectomy cases. X axis denotes the preference to periodontal dressing after frenectomy and Y axis denotes the number of the patients involved in the study. The preference for periodontal dressing in frenectomy cases was 82.6%



**Figure 5:** This graph represents the association between the frenectomy and frenotomy procedures and the gender of patients involved in the study. X axis denotes the frenectomy and frenotomy procedure and Y axis denotes the number of the patients involved in the study. The graph shows that more number of female patients underwent frenectomy (43.66%) and frenotomy (16.90%) procedures when compared to males.

Pearson chi square value is 0.787 and p value is 0.78 ( > 0.05), hence the association was found to be statistically not significant.