

Reliability of the iliolumbar ligament in identification of lumbosacral transitional vertebra (LSTV) in lumbar spine magnetic resonance imaging

Ramezan Jafari^{1*}, Mohammad Javanbakht², Mahsa Mozaffari³, Ayla Jafari⁴, Hamid Hesarikia⁵, Amirhossein Najafi Almooti¹

¹Department of Radiology, Baqiyatallah University of Medical Sciences, Tehran, Iran

²Nephrology and Urology Research Center, Clinical Science Institute, Baqiyatallah University of Medical Sciences, Tehran, Iran

³Department of Neonatology, Aliasghar Children's Hospital, School of Medicine, Iran University of Medical Sciences, Tehran, Iran

⁴School of Pharmacy, Shahid Beheshti University of Medical Sciences, Tehran, Iran

⁵Department of Orthopedics, Baqiyatallah University of Medical Sciences, Tehran, Iran

ABSTRACT

Background: The lumbosacral transitional vertebra (LSTV) is a relatively common congenital anomaly of the vertebrae. LSTV identification is of great importance in presurgical planning and as a cause of lower back pain and early disc degeneration. Overwhelming evidence indicates that whole spine in magnetic resonance imaging (MRI) was capable of counting vertebrae and determining transitional vertebrae. It is also unknown whether the routine lumbosacral MRI protocol is capable of identifying LSTV using the level of iliolumbar ligament (ILL). The purpose of this study was to evaluate the diagnostic value (sensitivity and specificity) of the ILL in identification of LSTV.

Methods: Patients underwent whole spine MRI without contrast. Then, accurate numeration of spinal segments starting from 2nd cervical vertebra (C2) was also done as a gold standard for counting vertebrae. In addition, three additional axial T2W cuts from least two vertebral bodies were taken for evaluation of ILL attachment.

Among 210 enrolled patients, 178 patients had normal number of vertebra with bilateral ILL attached to the L5, and 32 patients had LSTV (15.2%), of which 29 patients had ILL attached to the L5, and 3 patients did not have ILL; therefore, the ILL specificity and sensitivity were calculated to be 98.3% and 100%, respectively.

Conclusion: The ILL revealed considerable specificity and sensitivity for identification of LSTV and can therefore be routinely used in the diagnosis of LSTV in lumbosacral MRI.

Corresponding Author e-mail: rezajafari201089@gmail.com

How to cite this article: Jafari R, Javanbakht M, Mozaffari M, Jafari A, Hesarikia H, Almooti N A (2023), Reliability of the iliolumbar ligament in identification of lumbosacral transitional vertebra (LSTV) in lumbar spine magnetic resonance imaging. Journal of Complementary Medicine Research, Vol. 14, No. 6, 2023 (pp. 188-191)

INTRODUCTION

Lumbosacral transitional vertebra (LSTV) is defined as a congenital anomaly in the lumbosacral spine, that a fusion of the enlarged transverse process of the last lumbar vertebra with the sacrum can be observed, and has been described as a partial or complete 5th lumbar vertebra sacralization to lumbarized 1st sacral vertebra (partial or complete), [1, 2, 3]. Based on the Castellvi classification, 4 types have been defined for LSTV as follows: type I: unilateral or bilateral enlargement and dysplasia of transverse process, type II: unilateral or bilateral pseudoarticulation of the transverse process with sacrum (incomplete lumbarization or sacralization), type III: unilateral or bilateral fusion of transverse process with the sacrum (complete lumbarization or sacralization), and type IV: type II on one side and type III on other side.

The prevalence of LSTV in different populations varies according to diagnostic modalities, ranging from 4% to 36% [1, 4, 5, 6]. The prevalence has been estimated to be higher in men when comparing with women [7]; some studies also point to the role of genetics in its development, where mutation in HOX10/HOX11 genes has been indicated to contribute to LSTV [5, 6]. However, its association with low back pain (LBP) is a controversial issue.

KEYWORDS:

Low back pain, MRI, lumbosacral transitional vertebra (LSTV), iliolumbar ligament (ILL).

ARTICLE HISTORY:

Received: Jun 14, 2023

Accepted: Jul 11, 2023

Published: Aug 09, 2023

DOI:

10.5455/jcmr.2023.14.06.17

It has been found that the prevalence of LSTV in patients with LBP varies between 4.6% and 7% and this abnormality is seen in 11.4% of patients under 30 years of age [8, 9]. Previous radiographic studies have shown that LSTV II and IV types are fully linked to LBP [7,4]. Others believe that lumbosacral transitional segments are not more common in patients with low back pain [10, 11, 12, 13]. Parameters are suggested to determine the level of the last vertebral body in LSTV or segmentation abnormalities, e.g., iliolumbar ligament (ILL) for the L5 vertebral body [14]. The ILL raised from the last lumbar vertebra, L4, L5, or L6, depending on the spine segmentation [15].

ILL origin could be an appropriate marker for L5 identification in the presence of a transitional lumbosacral junction. Sagittal and axial MRI with coronal localizer images has been proposed to be very helpful in providing a favorable description of transitional lumbosacral junction and attachment site of ILL to transverse process of which vertebrae [3,16].

According to high prevalence of LSTV, if we can't diagnosed it correctly in lumbar spine MRI, The likelihood of misdiagnosis and mislevel increases. In spinal MRI axial cuts are routinely obtained from disc space and endplates, so the ILL is not seen well and by doing a few additional axial cuts from vertebral bodies the ILL is clearly visible.

Therefore, the aim of this study was to determine the diagnostic value (sensitivity and specificity) of the ILL in identification of LSTV in patients referred to our Hospital.

MATERIALS AND METHODS

This is a cross-sectional study enrolled 210 patients attending the Radiology clinic of Baqiyatallah Hospital (Tehran, Iran) for evaluation of low back pains or radiculopathy during the period from February 2018 to June 2019. Patients have undergone whole spine MRI by any reason such as low back pain or spinal column pains. Furthermore, no restrictions were imposed on patient age and gender.

We assessed the findings of Whole Spine MRI images performed in the Hospital, and three additional axial cuts were made from the L5 and S1 vertebrae. Patients don't meet any of the following criteria at the start of treatment are not eligible for the investigation: Inclusion criteria included: All candidates for Whole Spine MRI in our Hospital were enrolled without age and sex limitations. Exclusion criteria: Patients with a history of severe pelvic or spinal traumatic fracture, previous lumbar spine surgery or severe spine deformity such as blocked vertebrae which disrupts the correct numbering of vertebral bodies.

A 1.5 Tesla avanto magnetic resonance imaging (MRI) scanner Siemens (Germany) was used for patients and contrast was not used in this study. In addition to the sagittal T1-Weighted (T1w) and T2-Weighted (T2w) and STIR images of the whole spine and axial T2W images from disc spaces and endplate, three additional axial T2W cuts from each lower lumbar and upper sacral vertebral bodies were taken, and sagittal T2 weighted

image of the entire spine were also provided Then all MRI exams were evaluated by two radiologists with 8 and 10 year experience. The inter-observer coefficient agreement between the two radiologists were determined ($r=0.98$; $P= 0.0001$). Vertebral bodies were counted from C2 to S1 (Fig 1) To perform the statistical analysis, data were allocated to each of the upper and lower parts of the vertebral bodies and intervertebral discs by dividing the T12-L1 vertebral disc (No. 1) and the lower half of L5 vertebra (No. 15). After collecting data on vertebral surfaces associated with ILL, the data were entered into SPSS statistical software and then analyzed.

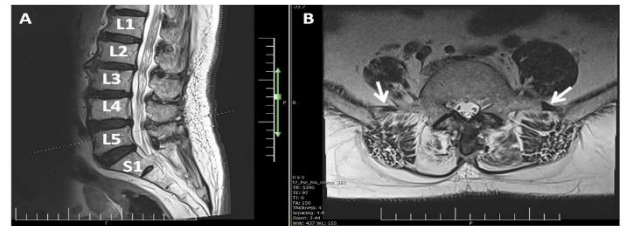

Figure 1: Sagittal T2W total spin MRI image shows normal numbering of spinal column without LSTV

This study was approved by the Ethics Committee of Baqiyatallah University of Medical Sciences. This study follows the guidelines of the Helsinki Declaration. It is worth noting that no additional costs were imposed on patients.

Data analysis

Sample size was calculated using G-power 31.3 for Windows. Statistical analysis was performed using SPSS software version 21 (SPSS Inc., Chicago, IL). Descriptive analysis was done using means, standard deviation, and percentage for the usual variables. A p value of <0.05 was considered as statistically significant.

RESULTS

In this study, 210 patients were evaluated, of which 101 were females and 109 were males (Table 1). The results showed that 178 patients had normal number of vertebra with bilateral ILL and in all of them the ILL was attached to the transverse process of L5, and 32 patients had LSTV, of which 14 were females and 18 were males (Table 2). The prevalence of LSTV in our study is 15.2%, which 29 of them had unilateral or bilateral ILL and in all of them the ILLs was attached to the transverse process of L5, and 3 patients did not have ILL due to complete sacralization and bilateral fusion of the transverse process of L5 to S1.

Table 1: Lumbosacral transitional vertebrae (LSTV) and gender Crosstabulation

			Gender		Total
			Females	Males	
LSTV	YES	Count	14	18	32
		percent	43.8%	56.3%	100.0%
	NO	Count	87	91	178
		percent	48.9%	51.1%	100.0%

		percent	48.9%	51.1%	100.0%
Total		Count	101	109	210

Table 2: Lumbosacral transitional vertebrae(LSTV) and ILL Crosstabulation

			ILL		Total
			PRESEN T	ABSENT	
LSTV	YES	Count	29	3	32
		percent	90.6%	9.4%	100.0%
	NO	Count	178	0	178
		percent	100%	0%	100.0%
Total		Count	207	3	210
		% of Total	98.5%	1.5%	100.0%

The specificity of the ILL in determining the LSTV was calculated in patients. Our findings revealed that 32 patients had LSTV, of which 29 patients had ILL and in all of them the ILL was attached to the transverse process of L5 (Fig 2) and 3 patients did not have ILL due to complete bilateral fusion of the transverse process of L5 to S1. According to the specificity formula, the ILL specificity was determined as 98.3%.and the sensitivity of the ILL in determining the LSTV was determined to be 100% as calculated by the sensitivity formula

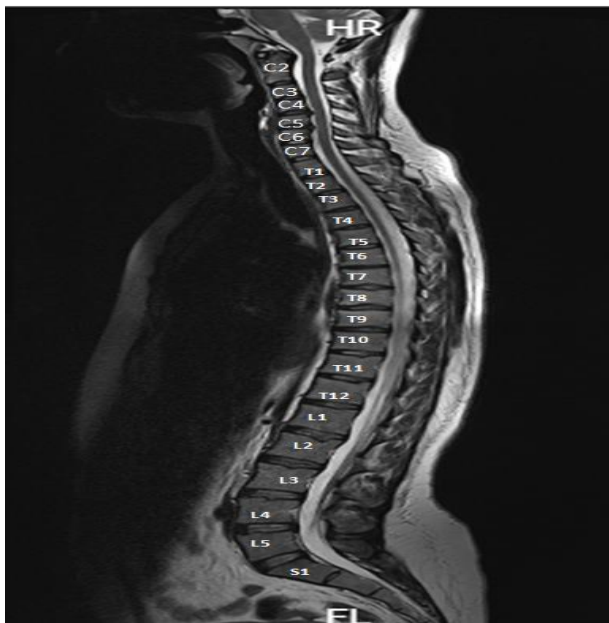


Figure 2: Sagittal (A) and axial (B) T2W MRI images shows dark signal iliolumbar ligaments connecting to transverse process of L5 vertebrae bilaterally.

According to the following formulas, positive and negative predictive values of ILL were determined as 100 and 98.3% for LSTV, respectively.

$$\text{Positive predictive value} = \frac{29 \text{ (True Positive)}}{29 \text{ (True Positive)} + 0 \text{ (False Positive)}}$$

$$\text{Negative predictive value} = \frac{178 \text{ (True Negative)}}{178 \text{ (True Negative)} + 3 \text{ (False Negative)}}$$

DISCUSSION

Low back pain is a common problem that many people face throughout their lives. Bertolotti's syndrome has been indicated a possible association of the congenital LSTV and low back pain. Surgery can hopefully improve back pain. One of the ways to diagnose LSTV is to use the origin of the ILL in radiography or MRI, which can show LSTV in these modalities.

Misinterpretation of LSTV has been suggested to be linked to incorrect spinal counts, resulting in poor surgical consequences due to errors in spinal level diagnoses. Therefore, in order to prevent errors in the spinal level diagnosis, the likelihood of LSTV should be identified that could be evaluated by a whole spine X-ray [17].

LSTV has been considered to be a common normal variant in the in the Australian population that can have significant consequences for spine surgery. Spine surgeons and radiologists should consider LSTV, most experts believe that LSTV is well visible in anteroposterior (AP) radiographs, however some emphasize the Ferguson view (angled at 30 degrees), [14, 18, 19].

Magnetic resonance imaging (MRI) has also been suggested to find ILL, which thought to origin from the L5 transverse processes, but cannot be helpful in anomalies of thoracolumbar junction [1, 18]. Numerical variants of the spine have been commonly found when compared with LSTV (2.5 times). Only whole-spine imaging has been suggested to be capable of diagnosing numerical variants and the anatomical nature of LSTV, where mobile vertebrae was higher in men, while it showed decreasing tendency in women [20].

In a study by O'Driscoll et al. (1996), the results showed that LSTV can be visualized on sagittal MRI scan, where a good association of fused LSTV and a type 4 MRI appearance was found [21].

A study by Delport et al. (2006) indicated that 30% of consecutive patients Showed LSTV. Of the 210 patients studied in the present study, 101 were females and 109 were males, 32 (15%) had LSTV, of which 14 were females and 18 males [22].

The prevalence of LSTV has been found to be higher in men than women (28.1% vs. 11.1%), [7], where the results of the above study were similar to those of our study. A study performed to evaluate the ability of anatomical landmarks for recognition of the lumbar vertebra level among LSTV individuals (71 subjects), which indicated a whole spine image was capable of numbering the lumbar vertebra as a gold standard [23].

Based other results presented herein, MRI is an acceptable modality for the diagnosis of LSTV and the ILL can be used to detect this anomaly. In our study, 98% of subjects with LSTV had ILL.

However, the ILL once has been indicated to be capable of recognizing L5-vertebra as reported previously to be a reliable structure [14], but demonstrated to be unreliable for detection of the L5 vertebra in the setting of an LSTV by evaluation of 770 patients with LSTV [24]. Furthermore, another study indicated that LSTV is more common in patients with low back pain and the ILL could not be able to identify L5 vertebra [3]. The results of mentioned studies were not in line with our results. A study evaluated the ability of Anatomical Landmarks (CF, AB, IC, RRA, CT, SR, ILL, and PM) in detection of Transitional Vertebra, which concluded that ILL can be commonly used in the diagnosis of LSTV, but its accuracy is not 100% [25], so the results of the above study are consistent with our study.

CONCLUSION

According to the results obtained herein, the use of ILL has a very high specificity and sensitivity for LSTV identification and can be used in identifying ILL and LSTV in lumbar spine MRI, if it's done in the manner which described in this study.

CONFLICT OF INTEREST

None

REFERENCES

- Konin GP, Walz DM. Lumbosacral transitional vertebrae: classification, imaging findings, and clinical relevance. *AJNR American journal of neuroradiology*. 2010;31(10):1778-86.
- Mahato NK. Redefining lumbosacral transitional vertebrae (LSTV) classification: integrating the full spectrum of morphological alterations in a biomechanical continuum. *Medical hypotheses*. 2013;81(1):76-81.
- Shaikh A, Khan SA, Hussain M, et al. Prevalence of Lumbosacral Transitional Vertebra in Individuals with Low Back Pain: Evaluation Using Plain Radiography and Magnetic Resonance Imaging. *Asian Spine J*. 2017;11(6):892-897. doi:10.4184/asj.2017.11.6.892
- Tang M, Yang XF, Yang SW, Han P, Ma YM, Yu H, et al. Lumbosacral transitional vertebra in a population-based study of 5860 individuals: Prevalence and relationship to low back pain. *European journal of radiology*. 2014;83(9):1679-82.
- Paik NC, Lim CS, Jang HS. Numeric and morphological verification of lumbosacral segments in 8280 consecutive patients. *Spine*. 2013;38(10):E573-8.
- Jancuska JM, Spivak JM, Bendo JA. A Review of Symptomatic Lumbosacral Transitional Vertebrae: Bertolotti's Syndrome. *Int J Spine Surg*. 2015;9:42. Published 2015 Jul 29. doi:10.14444/2042
- Nardo L, Alizai H, Virayavanich W, Liu F, Hernandez A, Lynch JA, et al. Lumbosacral transitional vertebrae: association with low back pain. *Radiology*. 2012;265(2):497-503.
- Holm EK, Büniger C, Foldager CB. Symptomatic lumbosacral transitional vertebra: a review of the current literature and clinical outcomes following steroid injection or surgical intervention. *SICOT J*. 2017;3:71. doi:10.1051/sicotj/2017055
- Elster AD (1989) Bertolotti's syndrome revisited. *Transitional vertebrae of the lumbar spine*. *Spine* 14, 1373-1377.
- Secer M, Muradov JM, Dalgic A. Evaluation of congenital lumbosacral malformations and neurological findings in patients with low back pain. *Turkish neurosurgery*. 2009;19(2):145-8
- Peterson CK, Bolton J, Hsu W, Wood A. A cross-sectional study comparing pain and disability levels in patients with low back pain with and without transitional lumbosacral vertebrae. *Journal of manipulative and physiological therapeutics*. 2005;28(8):570-4.
- Luoma K, Vehmas T, Raininko R, Luukkonen R, Riihimäki H. Lumbosacral transitional vertebra: relation to disc degeneration and low back pain. *Spine*. 2004;29(2):200-5.
- Otani K, Konno S, Kikuchi S. Lumbosacral transitional vertebrae and nerve-root symptoms. *The Journal of bone and joint surgery British volume*. 2001;83(8):1137-40. 33.
- Hughes RJ, Saifuddin A (2006) Numbering of lumbosacral transitional vertebrae on MRI: role of the iliolumbar ligaments. *AJR Am J Roentgenol* 187:W59-W65
- Bressler EL. Numbering of lumbosacral transitional vertebrae on MRI. *AJR American journal of roentgenology*. 2007;188(2):W210. author reply W1.
- Carrino JA, Campbell PD, Jr, Lin DC, Morrison WB, Schweitzer ME, Flanders AE, et al. Effect of spinal segment variants on numbering vertebral levels at lumbar MR imaging. *Radiology*. 2011;259(1):196-202
- Nakagawa T, Hashimoto K, Tsubakino T, Hoshikawa T, Inawashiro T, Tanaka Y. Lumbosacral Transitional Vertebrae Cause Spinal Level Misconception in Surgeries for Degenerative Lumbar Spine Disorders. *Tohoku J Exp Med*. 2017;242(3):223-228. doi: 10.1620/tjem.242.223.
- French HD, Somasundaram AJ, Schaefer NR, Laherty RW. Lumbosacral transitional vertebrae and its prevalence in the Australian population. *Global Spine J*. 2014;4(4):229-232. doi:10.1055/s-0034-1387808
- Hinterdorfer P, Parsaei B, Stieglbauer K, Sonnberger M, Fischer J, Wurm G. Segmental innervation in lumbosacral transitional vertebrae (LSTV): a comparative clinical and intraoperative EMG study. *J Neurol Neurosurg Psychiatry*. 2010;81(7):734-741.
- Tins BJ, Balain B. Incidence of numerical variants and transitional lumbosacral vertebrae on whole-spine MRI. *Insights Imaging*. 2016 Apr;7(2):199-203. doi: 10.1007/s13244-016-0468-7.
- O'Driscoll CM, Irwin A, Saifuddin A. Variations in morphology of the lumbosacral junction on sagittal MRI: correlation with plain radiography. *Skeletal Radiol*. 1996;25(3):225-30.
- Delport EG, Cucuzzella TR, Kim N, Marley J, Pruitt C, Delport AG. Lumbosacral transitional vertebrae: incidence in a consecutive patient series. *Pain Physician*. 2006 Jan;9(1):53-6.
- Farshad-Amacker NA, Aichmair A, Herzog RJ, Farshad M. Merits of different anatomical landmarks for correct numbering of the lumbar vertebrae in lumbosacral transitional anomalies. *Eur Spine J*. 2015 Mar;24(3):600-8. doi:10.1007/s00586-014-3573-7.
- Farshad-Amacker NA, Lurie B, Herzog RJ, Farshad M (2014) Is the iliolumbar ligament a reliable identifier of the L5 vertebra in lumbosacral transitional anomalies? *Eur Radiol*. doi:10.1007/ s00330-014-3277-8
- Jagannathan D, Indiran V, Hithaya F, Alamelu M, Padmanaban S. Role of Anatomical Landmarks in Identifying Normal and Transitional Vertebra in Lumbar Spine Magnetic Resonance Imaging. *Asian Spine J*. 2017 Jun;11(3):365-379. doi:10.4184/asj.2017.11.3.365.