

RESEARCH ARTICLE

Evaluation of MRI findings in patients with the first episode of seizures

MAHYAR MOHAMMADIFARD¹, ELHAM RAHIMIAN^{2*}, ELHAM PISHNAMAZ¹, MAJID.R TAHSINI³

¹Department of Radiology, Imam Reza Hospital, Birjand University of Medical Sciences, Birjand, Iran

²Neuroradiologist, Haghghat Medical Imaging Research Center, Tehran, Iran, Email: rahimian86@gmail.com

³Biomedical Engineering, Haghghat Medical Imaging Research Center, Tehran, Iran

*Corresponding Author

ABSTRACT

Introduction: Finding the cause of seizures has always been one of the most important problems for physicians. Magnetic resonance imaging (MRI) imaging in patients with seizures is one of the most important imaging modalities in detecting the structural abnormalities in seizures. Therefore, the aim of this study was to evaluate the prevalence of abnormal findings in the MRI of patients with the first episode of seizure.

Materials and Methods: This descriptive cross-sectional study was performed on patients referred to two imaging centers with (3T trio Siemens and 1.5T Avanto) with the first episode of seizure. Initially, the report of clinical diagnostic measures and demographic characteristics as well as clinical history, neurological examination and then MRI report were collected in a special checklist. MRI was performed by two MRI machines (3T trio Siemens and 1.5T Avanto) with dedicated protocol of seizure. After data collection, analyzing the data by SPSS software version 19 was performed and final results were extracted.

Results: A total of 1576 patients with a mean age of 30.1 years were evaluated, of whom 776 (49.2%) were female. The type of seizure was generalized in 1478 patients (93.8%) and focal in other patients. Abnormal findings were detected in MRI images of 619 patients (39.3%), the most common of which were temporal sclerosis in 193 patients (12.2%) and scar and gliosis in 117 patients (7.4%). The most lesions were found in the temporal lobe of 265 patients (45.5%). The frequency of normal and abnormal MRIs were significantly different between the sexes ($P = 0.011$), between different age groups ($P < 0.001$) and also between focal and generalized seizures ($P < 0.001$).

Conclusion: Regarding to importance of MRI with dedicated protocol in detection of structural abnormalities in seizure, we tried to perform demographic study and categorizing the structural abnormalities in a large number of cases to prove role of MRI even in the first attack of seizure and also to emphasize on importance of early MRI on diagnosis and management of cases. However further investigation are needed to evaluate the role of MRI as the early imaging modality even in the first attacks seizure cases ..

KEYWORDS:

Magnetic resonance imaging, seizures, MRI.

ARTICLE HISTORY:

Received Oct 20, 2021

Accepted Nov 02, 2021

Published Dec 11, 2021

DOI:

10.5455/jcmr.2021.12.04.29

VOLUME: 12

ISSUE: 4

ISSN: 2146-8397

INTRODUCTION

Seizure is a disorder of the nervous system caused by sudden and severe electrical discharge of nerve cells and is the most common neurological disease in children and adults. Due to its chronic nature and high prevalence, this disease has many direct and indirect effects on people's quality of life. Seizure manifest itself with behavioral, motor, sensory and/or autonomic dysfunction. Seizure also can present as an emergency condition that

accounts for about 1.2% of emergency referrals and 1.4% of hospital admissions in the United States and Europe, of which 24% are referred as first-time seizures (1-3).

The first step in dealing with seizure is to diagnose and treat the underlying cause, which can be prevented by timely diagnosis and treatment of many long-term physical and mental disabilities as well as irreversible changes in the nervous system in the future. A clinical history and careful physical examination are important tools as the first step. Blood samples should be taken immediately to measure

glucose, calcium, magnesium, electrolytes, and urea nitrogen, and hypoglycemia and bacterial meningitis should be also ruled out. Brain imaging is recommended for all patients with seizure, whose seizures are not justified by abnormal glucose, calcium, or serum electrolytes (4). Different types of epileptic seizures have been identified so far, which are divided into Generalized Tonic-Clonic Seizures and absence seizure as well as partial seizures (i.e., simple and partial seizures [temporal lobe, psychomotor]) (5).

The etiology of seizures is variable and sometimes multifactorial. Treatment outcomes depend to a large extent on the underlying cause of the seizure (6). After epilepsy, cerebrovascular diseases, cranial trauma, primary or metastatic brain tumors, central nervous system infections, and metabolic disorders are other major causes of seizures (7, 8).

EEG abnormalities account for a higher percentage of seizure causes. CT scan and MRI are also in the next categories. Although a percentage of abnormalities were reported by laboratory findings, they are a minor diagnostic criterion. History and physical and neurological examinations are useful, but do not provide sufficient information to physicians (9).

Given the availability of various laboratory studies, electroencephalograms, CT scans, and MRIs, there is still little information on the management of these seizures. Most of the time, doctors are confused about the use of imaging procedures (MRI, CT scan), as well as when the cause of seizures is alcohol overdose or medical procedures (10-12). MRI is the most important diagnostic tool in detecting structural disorders that predispose to seizures (i.e., mesial temporal sclerosis and developmental cortex, cavernoma, vascular malformations, and perinatal lesions). It is also helpful in identifying causes of drug resistance epilepsy (13, 14).

Therefore, this study was performed to evaluate the lesions leading to seizure in MRI of patients with the first episode of seizure referred to the hospital and imaging center.

MATERIALS AND METHODS

This descriptive cross-sectional study was performed on patients referred to two referral imaging centers with the first episode of seizures from 2009 to 2017. Patients were selected through purposive non-probabilistic sampling. Patients with inclusion and exclusion criteria were included in the study.

Inclusion criteria include

patients with the first episode of seizure, no pregnancy, no

history of trauma, no history of fever and seizure, no previous known lesion or recent brain surgery, and age over 10 years.

Exclusion criteria

incomplete information.

Sample size

According to the inclusion criteria, 2000 patients from two referral imaging centers were enrolled in the study from 2009 to 2017.

Procedure

Initially, the report of clinical diagnostic measures and demographic characteristics were extracted from the medical records by the radiology resident. Also, history, neurological examination and MRI report and personal details were collected in a special checklist.

Brain MRI was performed on a 1.5 T Siemens Avanto and 3T Trio scanners with an unenhanced 3D T1-weighted gradient-echo sequence (MPRAGE) with 176 axial slices (voxel size of 1 mm × 1 mm × 1 mm), T2 Axial and Sagittal, FLAIR Coronal and T2 SPACE dark fluid sequences.

Data analysis

After collecting the data, their file was created in SPSS software 19. Data were analyzed by Chi-square test or Fisher's exact test at a significance level of 0.05. Data were also presented descriptively.

Ethical considerations

A written letter of introduction was obtained from the university authorities for related research centers. The information of all patients was kept confidential. In all stages of the research, all ethical declarations of Helsinki research and ethics research committees of the University of Medical Sciences were considered (Ethics code: IR.BUMS.REC.1399.388).

RESULTS

In the present study, a total of 1576 patients were included. The mean age of patients was 14.1± 30.1 years. Also, 776 patients (49.2%) were female and the rest were male. Furthermore, the type of seizure was found to be generalized seizure in 1478 patients (93.8%), followed by focal seizure in other patients (Table 1).

Table 1: Frequency distribution of sex, age and type of seizure

Properties		frequency	percent
Sex	female	776	49.2
	male	800	50.8
Type of seizure	Generalize	1478	93.8
	focal	98	6.2
Age of seizure	10 to 19 years	426	27
	20 to 29 years	431	27.3
	30 to 39 years	361	22.9
	40 to 49 years	193	12.2
	50 to 59 years	95	6
	60 to 69 years	46	2.9
	70 years and more	24	1.5

Table 2 and Figure 1 show the MRI findings of the patients studied. As can be seen, MRI of 957 patients (60.7%) was normal, followed by temporal sclerosis (193 patients; 12.2%) and scars and gliosis (117 patients; 7.4%).

Table 2: Frequency distribution of MRI image findings

findings MRI	Frequency	Percent
normal	957	60.7
abnormal	619	39.3
Temporal sclerosis	193	12.2
Scar and gliosis	117	7.4
Non-proprietary foci	42	2.7
Age related atrophy	29	1.8
FCD IIa	20	1.3
FCD (IIb)	18	1.1
Ventricular asymmetry	17	1.1
Global atrophy	16	1.0
Abnormal gyration	15	1.0
Cavernoma	11	0.7
Glioma	11	0.7
Extensive heterotopia	11	0.7
Atrophy and Thinning in the corpus callosum	10	0.6
Subependemal heterotopia	10	0.6
Other cases	99	6.3
total	1576	100

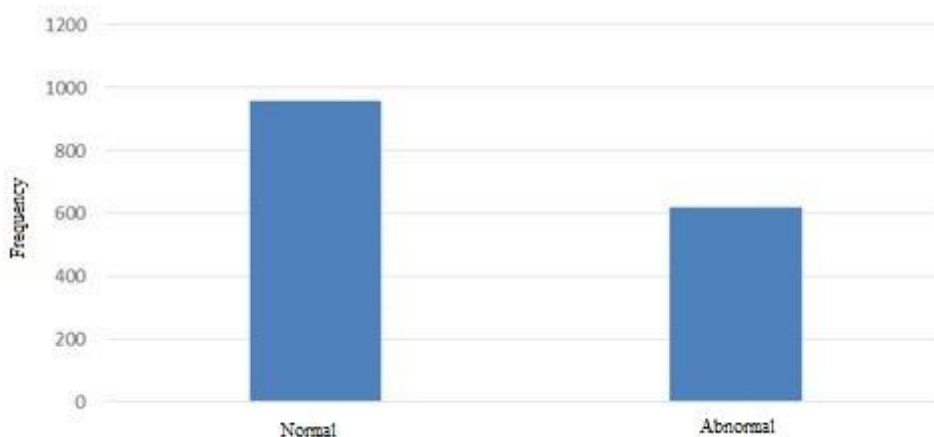


Fig.1: Normal and abnormal findings in the studied patients

Table 3 examined the frequency distribution of the lesion site in patients. The most lesions were in the temporal lobe (265 patient; 45.5%) and the least lesions were in the parietal (9 patients; 1.5%).

Table 3: Frequency distribution of the lesion site

Lesion place	Frequency	percent
Temporal	265	45.5
Frontal	62	10.6
vOccipital	23	3.9
Parietal	9	1.5
Periventricular	56	9.6
Fronto-temporal	18	3.1
Parieto-otemporal	13	2.2
Foronto-parietal	22	3.8
Parieto-occipital	23	3.9
Hemisphere	92	15.8
Total	583	100

The frequency of the distribution of lesion in Brain MRI was examined. The results showed that the involvement in the right (221; 38.4%) was more than the left side (197; 34.2%). Frequency distribution of focal seizures in patients was examined as well and 137 patients (14%) showed temporal lobe seizure with unknown side, followed by left temporal lobe (20 patients; 21.5%), right temporal lobe (16 patients; 17.2%), right frontal lobe (18 patients; 19.4%), left frontal and bilateral frontal lobe (5 patients; 5.4%) and others (21 patients; 17.1%).

Table 4 shows the normal or abnormal status of MRI based on

the sexes, and age ranges, as well as type of seizure. The

frequency of normal and abnormal MRIs was significantly different between the two sexes ($P = 0.011$), and between different age groups ($P < 0.001$) as well as between focal and generalized seizures ($P < 0.001$).

Comparison of the type of lesion in MRI according to the type of seizure is summarized in Table 5. The results showed a significant difference between the lesions found in MRI in different types of seizures ($P = 0.018$), where 87% of focal seizures had normal MRI, but this amount was found to be 68.1% in generalized seizures.

Table 4: Comparison of MRI findings by sex, age ranges, and type of seizure

Properties		MRI normal	MRI abnormal	The result of Chi-square test with Fisher's exact test
Sex	female	496 (63.9%)	280 (36.1%)	$P=0.011$ $\chi^2= 6.54$
	male	461 (57.6%)	339 (42.4%)	
Type of seizure	generalize	877 (59.3%)	601 (40.7%)	$P<0.001$ $\chi^2= 19.2$
	focal	80 (81.6%)	18 (18.4%)	
Age	10-19	311 (73%)	115 (27%)	$P<0.001$ $\chi^2= 96.1%$
	20-29	272 (63.1%)	159 (36.9%)	
	30-39	218 (60.4%)	143 (39.6%)	
	40-49	96 (49.7%)	97 (50.3%)	
	50-59	44 (46.3%)	51 (53.7%)	
	60-69	16 (34.8%)	30 (65.2%)	
	> 70	0 (0%)	24 (100%)	

Table 6 compares the type of lesion on MRI by age. As can be seen, 82.7% of patients in the age group of 10 to 19 years had normal MRI, while this ratio was zero in the age group over 70 years.

Table 5: Comparison of lesion type on MRI by type of seizure

lesion MRI	Generalized seizure	Focal Seizure	Fisher's exact test result
Normal	877 (68.1%)	80 (87%)	$P=0.018$ $\chi^2=15.7$
Temporal sclerosis	188 (14.6%)	5 (5.4%)	
Non-proprietary foci	42 (3.3%)	0 (0%)	
Scar and gliosis	112 (8.7%)	5 (5.4%)	
Age atrophy	29 (2.3%)	0 (0%)	
Fcd2b	17 (1.3%)	1 (1.1%)	
FCD2a	3 (2%)	0 (0%)	
Non typable	19 (1.5%)	1 (1.1%)	

Comparison of different types of lesions observed in MRI by gender in the studied patients was evaluated. The results

showed that 496 female patients (72.6%) and 461 male patients (61.2%) had normal MRI lesions.

Temporal sclerosis was seen in 87 women (12.7%) and 106 men (15.2%), followed by nonspecific foci (244 women and 18 men), scar, and gliosis (51 women [7.5%] and 66 men [9.5%]), age atrophy (6 women [0.9%] and 23 men [3.3%], Fcd2b (9

men and women [1.3%]), lesion 2a (1 woman [0.1%] and 2 men [0.3%]) and non typable (9 women and 11 men). The results revealed that the normality of images in females was higher than males.

Table 6: Comparison of lesion type in MRI by age

Lesion found	10-19	20-29	30-39	40-49	50-59	60-69	> 70
NORMAL	311 (82.7%)	272 (73.1%)	218 (67.6%)	96 (58.2%)	44 (54.3%)	16 (40%)	0 (0%)
Temporal sclerosis	31 (8.2%)	38 (10.2%)	56 (17.3%)	39 (23.6%)	23 (28.4%)	4 (10%)	2 (9.1%)
Non-proprietary foci	5 (1.3%)	10 (2.7%)	10 (3.1%)	8 (4.8%)	5 (6.2%)	4 (10%)	0 (0%)
Scar and gliosis	25 (6.6%)	33 (8.9%)	33 (10.2%)	12 (7.3%)	4 (4.9%)	5 (12.5%)	5 (22.7%)
Age atrophy	0 (0%)	0 (0%)	0 (0%)	1 (0.6%)	3 (3.7%)	10 (25%)	15 (68.2%)
FCD2b	3 (0.8%)	9 (2.4%)	1 (0.3%)	3 (1.8%)	1 (1.2%)	1 (2.5%)	0 (0%)
2a	0 (0%)	1 (0.3%)	2 (0.6%)	0 (0%)	0 (0%)	0 (0%)	0 (0%)
Non typable	1 (0.3%)	9 (2.4%)	3 (0.9%)	6 (3.6%)	1 (1.2%)	0 (0%)	0 (0%)

DISCUSSION

Seizure is one of the most important cases of emergency department visits. Several reasons have been suggested for its occurrence, the rapid diagnosis of which is important (15). Therefore, the aim of this study was to evaluate MRI findings in patients with the first episode of seizures.

The results of the present study showed that there were no abnormal findings in MRI obtained in 60.7% of patients. In a study by Hakami et al., potential epileptogenic lesions were found in 23% of patients (16). In the study by Ho et al. (2013), 29% of patients had MRI lesions that could potentially be epileptogenic (17). Kalnin et al. (2008) conducted a study on children with the first episode of seizures who also found abnormal findings in 31% of their patients (18).

A higher proportion of the examined MRIs had abnormal findings in our study compared to the mentioned studies. However, another study conducted by Firoozabadi et al., MRIs of patients with generalized tonic-clonic seizures and other types of seizures were abnormal in 42.6% 76 and 76.9%, respectively, which are higher than the findings of this study (19). The reason for the differences between the results of different studies may be differences in methodology. For example, Hakami, et al. (16, 17) reported only lesions that could potentially be epileptogenic, but any abnormal findings were reported on MRI in the present study. Besides, the population studied in the study of Kalnin et al. (18) were children, which was different from the population of our study. In the study of Firoozabadi et al. (19), only 60 patients were evaluated, which was less than the sample size in the present study, and this low sample size may have caused errors in the analysis.

In the present study, the most common findings in patients with abnormal MRI were temporal sclerosis, scar and gliosis, which were found in 12.2% and 7.4% of patients, respectively. The most common finding in MRI of patients in the study of Firoozabadi et al. was hippocampal sclerosis (19). In the study of Hakami et al. (16), gliosis and encephalomalacia

were found to be the most common abnormal findings. Kalnin et al. (18) reported that ventricular enlargement and leukomalacia/gliosis were more common than other abnormalities. Finally, Ho et al. identified stroke lesions as the most common findings found in their patients' MRI (17). In general, there does not seem to be much correlation between the common lesions found in different studies. The cause of this cannot be said for sure, but issues such as patient age differences and racial differences may play a role.

Most abnormalities found in the patients of our study were in the temporal lobe, accounting for 45.5% of the abnormalities. There were also more involvements on the right than on the left. In other studies, relatively similar results were obtained, so that the most common site of abnormal lesions in the study of Firoozabadi et al. and Kalnin et al. was the temporal lobe (18, 19).

In this study, the ratio of male patients and patients with generalized seizures, who found abnormal findings in their MRI, was significantly higher than female patients and patients with focal seizures, respectively. It also appeared that abnormal findings were higher in older patients than in younger patients. In the study of Firoozabadi et al., abnormal lesions in MRI of patients over 30 years of age were significantly more than other patients (19).

However, contradictory results obtained by some studies with what we have found regarding the greater prevalence of lesions in patients with generalized seizures. In Hakami et al.'s study, MRI images were normal in 75% and 43% of patients with primarily generalized convulsive and generalized nonconvulsive seizures, respectively, but patients with convulsive and nonconvulsive focal seizures, 35% and 19% of patients had normal MRI, respectively (16). In the study of Firoozabadi et al., abnormal findings were found in 42.6% of patients with abnormal generalized tonic-clonic seizures, but 76.9% of patients with other types of seizures had abnormal findings (19).

The reason for the differences mentioned in the results of the present study and the results of other studies cannot be stated exactly. Regarding the large sample size of this study, the possibility of error in the present study seems to be less. In general, more studies are needed to further explain this issue.

CONCLUSION

We concluded that still MRI is one of the most effective imaging modalities in the diagnosis and management of the first episode of seizures to find the etiology of seizures. Various studies have linked different factors to abnormal lesions, and further investigation into the factors associated with abnormal findings requires further research.

REFERENCES

- Ozturk K, Soylu E, Bilgin C, Hakyemez B, Parlak M. Neuroimaging of first seizure in the adult emergency patients. *Acta Neurologica Belgica*. 2018;1-6.
- Williams J, Doherty J, Di Blasi C, Mabarak D, Kennedy U, Doherty CP. Seizure care in the emergency department. Identifying and bridging the gaps. A study of care and outcomes from 644 seizure presentations. *Epilepsy & Behavior*. 2018; 78: 226-31.
- Papandreou A, Danti FR, Spaul R, Leuzzi V, Mctague A, Kurian MA. The expanding spectrum of movement disorders in genetic epilepsies. *Developmental Medicine & Child Neurology*. 2020; 62(2):178-91.
- Abbott MB, Vlasses CH. Nelson textbook of pediatrics. *Jama*. 2011;306(21):2387-8.
- Tranvinh E, Lanzman B, Provenzale J, Wintermark M. Imaging evaluation of the adult presenting with new-onset seizure. *American Journal of Roentgenology*. 2019; 212(1):15-25.
- Esmailian M, Haghighi S, Aboutalebi A. Preventing Seizure due to Head Trauma in Patients Visiting Emergency Department. *Iranian Journal of Emergency Medicine*. 2018;5:13.
- Psychogenic Nonepileptic Seizures. *Journal of Neurology and Psychiatric Disorders*. 2019; 2(1):23-5.
- Kunze A, Reuber M. The first seizure as an indicator of epilepsy. *Current opinion in neurology*. 2018; 31(2):156-61.
- Acharya UR, Oh SL, Hagiwara Y, Tan JH, Adeli H. Deep convolutional neural network for the automated detection and diagnosis of seizure using EEG signals. *Computers in biology and medicine*. 2018; 100: 270-8 .
- Chhabra V, Gothwal SK, Gupta D, Sharma S, Bajaj P, Saini A. The clinical profile of seizures in an emergency setting. *J Dent Med Sci*. 2016; 15: 98-102.
- Bank AM, Bazil CW, editors. *Emergency management of epilepsy and seizures*. Seminars in neurology; 2019: Thieme Medical Publishers .
- Kotisaari K, Virtanen P, Forss N, Serbian D, Scheperjans F. Emergency computed tomography in patients with a first seizure. *Seizure*. 2017; 48: 89-93.
- Wellmer J, Quesada CM, Rothe L, Elger CE, Bien CG, Urbach H. Proposal for a magnetic resonance imaging protocol for the detection of epileptogenic lesions at early outpatient stages. *Epilepsia*. 2013;54(11):1977-87.
- Volturi S, Jayalakshmi S, Sahu S, Mohandas S. Clinical characteristics and factors associated with in-hospital mortality of convulsive status epilepticus in adult patients admitted to the neurointensive care unit. *International Journal of Epilepsy*. 2020, 16, (16-26)
- Crocker CE, Pohlmann-Eden B, Schmidt M. Role of neuroimaging in first seizure diagnosis. *Seizure*. 2017; 49: 74-8.
- Hakami T, McIntosh A, Todaro M, Lui E, Yerra R, Tan KM, et al. MRI-identified pathology in adults with new-onset seizures. *Neurology*. 2013;81(10):920-7.
- Ho K, Lawn N, Bynevelt M, Lee J, Dunne J. Neuroimaging of first-ever seizure: Contribution of MRI if CT is normal. *Neurol Clin Pract*. 2013;3(5):398-403.
- Kalnin AJ, Fastenau PS, deGrauw TJ, Musick BS, Perkins SM, Johnson CS, et al. Magnetic resonance imaging findings in children with a first recognized seizure. *Pediatric neurology*. 2008; 39(6):404-14.
- Dehghani Firuzabadi M, Mohammadifard M, Mirgholami A, Sharifzadeh GR, Mohammadifard M. MRI findings and clinical symptoms of patients with epilepsy referring to Valli-e-asr hospital between 2009 and 2010. *Journal of Birjand University of Medical Sciences*. 2013;19(4):422-9.