



Compensatory and adaptive changes in the dental alveolar complex in case of insufficient jaw size

N.V. Popova¹, O.I. Arsenina², K.M. Shishkin³, A.V. Popova⁴

¹National Medical Research Center of Dentistry and Maxillofacial Surgery, 119991, Timura Frunze str, 16, Moscow, Russia, ORCID: 0000-0002-3686-5263, Email: tusia_popova@mail.ru

²Professor, head of orthodontic department, vice-president of Russian Orthodontic Society, National Medical Research Center of Dentistry and Maxillofacial Surgery, 119991, Timura Frunze str, 16, Moscow, Russia, Russian Peoples Friendship University, Moscow, Russia, 117198, Mcluh-Maclaya str, 6, Moscow, Russia, ORCID: 0000-0002-0738-1227, Email: arsenina@mail.ru

³Clinic "Orthodont", Samara, 446011, Soviet army str, 240 B, 30, Samara, Russia, ORCID: 0000-0001-7895-1488, Email: mail@ortodont63.ru

⁴National Medical Research Center of Dentistry and Maxillofacial Surgery, 119991, Timura Frunze str, 16, Moscow, Russia, ORCID: 0000-0003-3713-606X, Email: anna.popova@yahoo.com

ABSTRACT

The research is based on an analysis of 1800 CT scans performed in patients undergoing orthodontic treatment since 2007 up to 2020. Various adaptive dentoalveolar changes by insufficient sizes of jaws the insufficient size of jaws and differences in the muscular-articulate balance were identified and systemized in four groups: (1) Adaptation of teeth position associated with jaw size insufficiency; (2) Adaptation of alveolar bone associated with jaw size insufficiency; (3) Adaptation of teeth position associated with muscle-articular balance; (4) Adaptation of teeth associated with space efficiency during the development process. Hence adaptive changes involve all dental alveolar structures influencing orthodontic treatment planning. Some of the changes may not be corrected.

ARTICLE HISTORY

Received February 11 2020,

Accepted March 04, 2020

Published August 20, 2020

KEYWORDS

CT, jaw size insufficiency, dentoalveolar structures, adaptive changes, root deformities.

Aim

identification of adaptive changes in the dental alveolar complex to the insufficient size of the jaws and variants of the muscular-articulatory balance.

Material and Methods

The study is based on the analysis of 1800 computed tomograms (CT) performed on patients who applied for orthodontic correction at the dental clinic "Orthodont" in Samara from 2007 to 2020 inclusive.

Results

The most common symptoms are the following:

- 632 (35.1%) patients had the vestibular tip of chewing teeth. Dental arches can be compensatorily expanded in case of jaws size in the decrease or their incompatibility.

- 195 (10.8%) patients had roots deformation due to the decreasing size of jaws.

- 43 (2.4%) patients had roots deformation due to compensatory adjustment of the teeth position change.

- 126 (7.0%) patients had a combination of tortoanomaly of teeth with insufficiency of the alveolar process.

* **Contact:** N.V. Popova,  National Medical Research Center of Dentistry and Maxillofacial Surgery, 119991, Timura Frunze str, 16, Moscow, Russia,  tusia_popova@mail.ru, phone: +79099353420

2020 The Authors. This is an open access article under the terms of the Creative Commons Attribution Non Commercial Share Alike 4.0 (<https://creativecommons.org/licenses/by-nc-sa/4.0/>).

- 47 (2.6%) patients had tortoanomaly of canines with insufficiency of the alveolar process behind the lateral incisors.
 - 59 (3.3%) patients had an hourglass shape of the alveolar process.
 - 24 (1.3%) patients had a trapezoidal shape of the alveolar process.
- The prevalence of other symptoms as follows:
- 28 (1.6%) patients had crowns of rudiments of permanent central incisors placed behind the roots of the same deciduous teeth.
 - 77 (4.3%) patients had roots of lateral incisors placed behind the roots of central.
 - 75 (4.2%) patients had tight placement of incisors roots.
 - 48 (2.7%) patients had a deep placement of incisors rudiments.
 - 131 (7.3%) patients had the vestibular position of incisors.
 - 62 (3.4%) patients had palatal placement of first premolars rudiments.
 - 55 (3.1%) patients had second premolars blocked.

INTRODUCTION

As a rule, the main arguments used to justify orthodontic correction are to improve the aesthetics of the face and smile, as well as the health of the teeth and periodontium. However, the link between orthodontic treatment and periodontal health remains controversial.

A literature review by J. Van Gastel et al. [6] from PubMed showed that crowding and orthodontic correction do not adversely affect periodontal tissue when patients have a high level of oral hygiene. The review included articles published between 1970 and 30 April 2007 (81 references). Another systematic review by AM Bollen et al. [5], across 8 databases and 6 dental journals (1980 to July 2006), found that there is no reliable evidence that orthodontic correction improves or worsens the periodontal condition, with 37 references cited. A literature review by Aous Dannan [3] also indicates that there is no reliable evidence of a positive effect of orthodontic treatment on the periodontal condition of patients. This review included articles published from 1964 to 2009, with links to 84 sources. Thus, the available data generally do not support the claim that orthodontic correction implies improved periodontal health. It is possible to assume that the dentoalveolar complex during the formation process adapts to the insufficient size of the jaws and variants of the muscular-articulatory balance.

AIM

identification of adaptive changes in the dental alveolar complex to the insufficient size of the jaws and variants of the muscular-articulatory balance.

MATERIALS AND RESEARCH METHODS

The study is based on the analysis of 1800 computed tomograms (CT) performed on patients who applied for orthodontic correction at the dental clinic "Orthodont" in Samara from 2007 to 2020 inclusive. Half of the CT scans were obtained on a Sirona Galileos cone-beam tomograph (registration certificate of the Ministry of Health of the Russian Federation 2002/579); the computer program supplied with the tomograph was used to view them. The other half of the CT scans were obtained on a Toshiba Aquilion 32 spiral computed tomograph (product registration number: FSZ 2007/00893) using the eFilmLite and Vitrea 2 programs. When analyzing CT, changes in the dentoalveolar complex were identified, reflecting adaptation to a decrease in the size of the jaws and options for muscle-articulation balance. The latter was assessed by its manifestation. The vestibular inclination of the teeth and the alveolar process reflects the predominance of the force applied to them from the side of the tongue, oral - from the vestibule of the oral cavity. The adaptation was understood as changes in the dental alveolar complex providing adaptation to the insufficient size of the jaws or the reduction of the dental alveolar arches due to the prevalence of forces applied from the vestibule. Of the forms of adaptation: orthoadaptation, disadaptation, compensation, only the latter was considered.

RESULTS AND DISCUSSION

Changes covered all elements of the dental alveolar complex: the position of the teeth; the shape of the crown and root, their proportionality; alveolar ridge. Manifestations of the main forms of criminatory reactions were noted: atrophy, hypertrophy, recombinant transformations. Changes in the position of the teeth were considered as recombinant transformations, which were studied according to causation. Atrophic and hypertrophic transformations were considered by the studied structures. Thus, all the adaptive changes in the dentoalveolar complex highlighted on CT were divided into four groups: 1. Adaptation of the position of the teeth in the alveolar process to the insufficient size of the jaws; 2. Compensatory and adaptive changes in the alveolar process in case of insufficient jaw size; 3. Adaptation of the position of the teeth in the alveolar bone to the muscular-articulatory balance; 4. Adaptive changes in teeth with limited space for their formation.

Adapting to the insufficient size of the jaws, the roots or rudiments of the teeth are placed in the alveolar process more compactly. If the rudiments of the incisors in the upper jaw, due to lack of space, cannot be located along the perimeter of the alveolar process, they are displaced palatally. With the most compact arrangement, the already

permanent central incisor is palatally displaced same name (Fig. 1).
from the temporary one of the

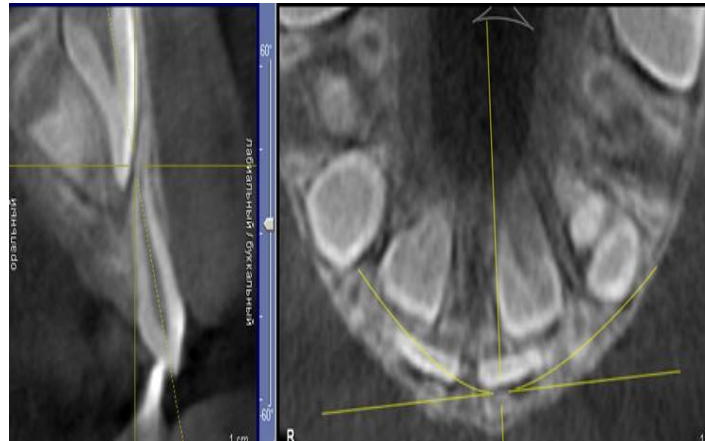


Fig. 1. The position of the crowns of the primordia of the permanent central incisors behind the roots of the temporary ones of the same name (patient IE).

The position of the roots of the lateral incisors behind the roots of the central ones also reflects a significant lack of space in the frontal region (Fig. 2.), while they are evenly located in the alveolar process.

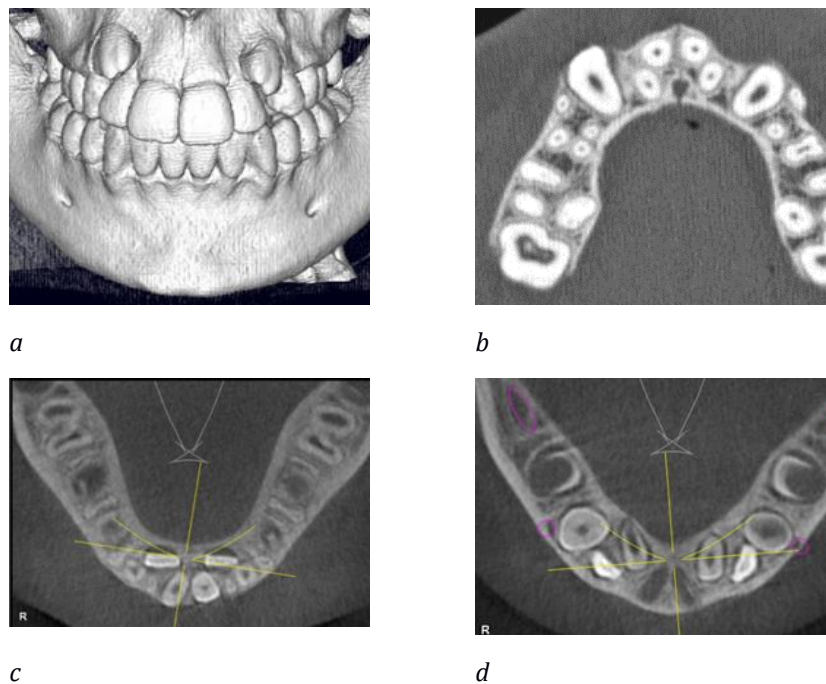


Fig. 2. The position of the roots of the lateral incisors behind the roots of the central (Fig.2a, 2b - patient V.V. ; Fig.2c, 2d - patient Kh.A.).

The crowns of the lateral incisors with the significant inclination can camouflage the palatal position of their roots. The lingual arrangement of the incisors on the lower jaw is rarely observed since the insufficiency of its size is combined with a small width of the alveolar process, more often the roots of the incisors are located tightly to each other, as if proceeding with their tops from one point and diverging as their mesiodistal diameter increases (Fig. 3.). Such a manifestation of the most compact arrangement of the incisors of the lower jaw is described in the literature as a "bouquet symptom" [1].

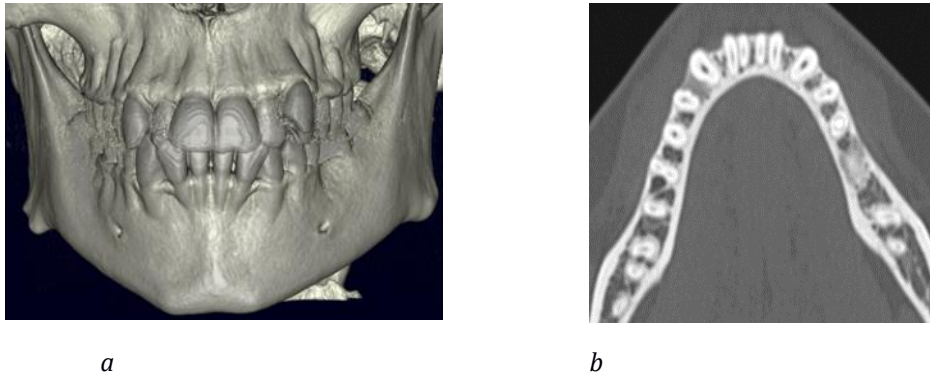


Fig. 3. Dense arrangement of the roots of the incisors (a, b) (patient M, D.).

The canine buds, adapting to the insufficient size of the jaws, are located as deep as possible in the alveolar process (Fig. 4.).

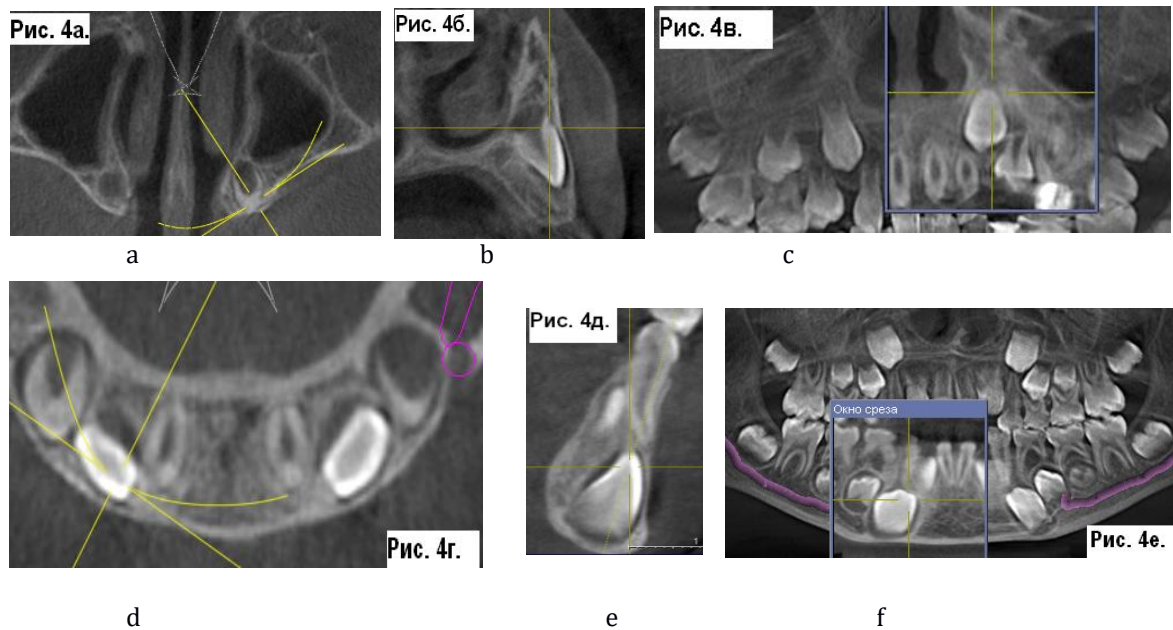


Fig. 4. Deep position of the canine buds (Fig. 4a, 4b, 4c - patient F.I. ; Fig. 4d, 4e, 4f - patient S.V.).

Thus, their crowns are located at the level of the roots of adjacent teeth and somewhat more vestibular, ensuring the maximum filling of the teeth with the volume of the alveolar process. Maintaining the vestibular position of the canines after their eruption (Fig. 5.) is also an adaptation to the insufficient size of the jaws.

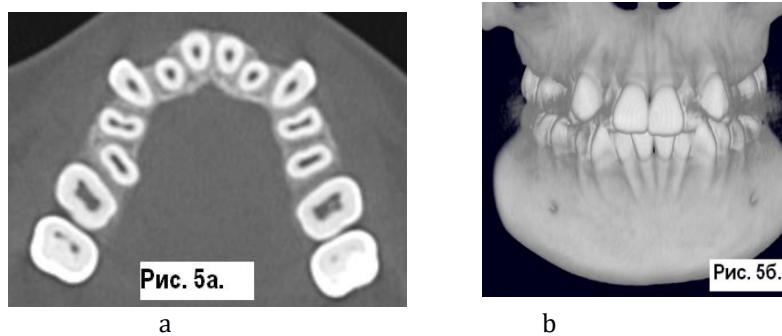


Fig. 5. The vestibular position of the canines (a, b) (patient Sh.Ya.).

The rudiments of the second premolars with a lack of space between the roots of the second temporary molars are located palatally from them and are oriented by their vestibule-oral diameter along the alveolar process. (Fig. 6.).

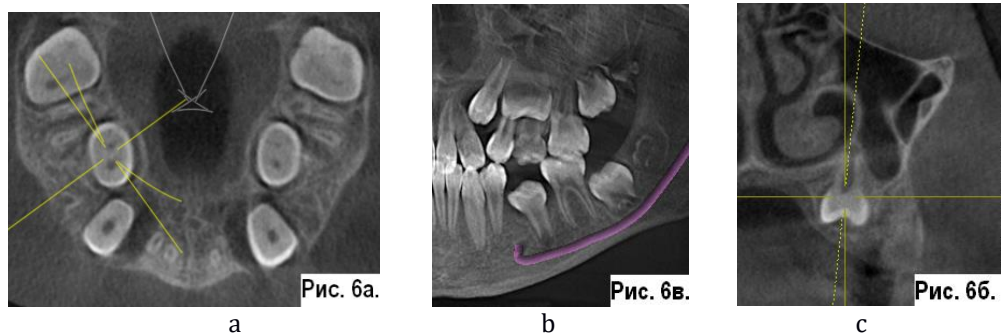


Fig. 6. Palatal position of the rudiments of the second premolars (a-c) (patient P.E.).

In cases where the width of the alveolar process is less than the vestibule-oral diameter of the teeth, they are located with this diameter along the alveolar process, that is, they are in tortoanomaly (Fig. 7.). This adaptation is characteristic of the canines and premolars of the lower jaw.

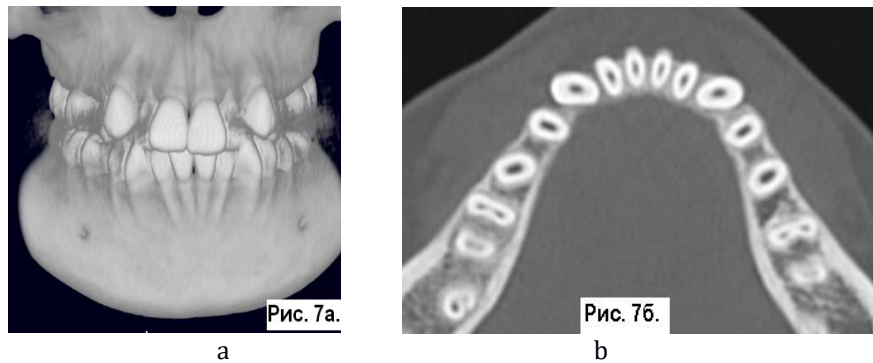


Fig. 7. Tortoanomalies of teeth with insufficient width of the alveolar process (a, b) (patient Sh.Ya.).

When the incisors of the lower jaw are arranged in the form of a "bouquet", behind the lateral incisor, a significant length deficiency in the width of the alveolar process is formed. The adjacent canine is rotated distally, so its root is better positioned in the alveolar process (Fig. 8.).

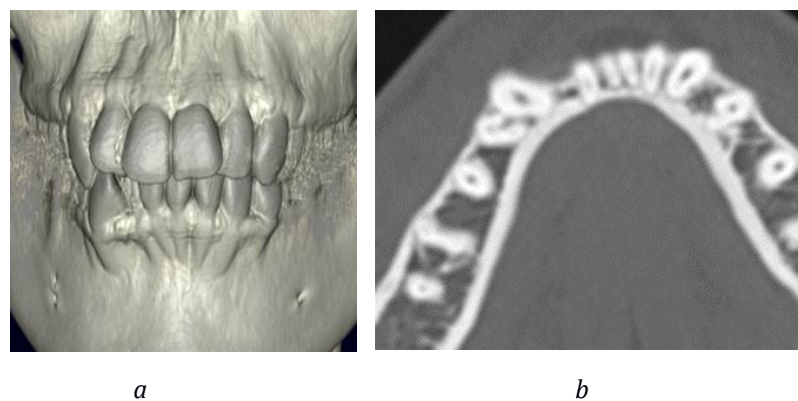


Fig. 8. Tortoanomaly of the canines in case of insufficiency of the alveolar process behind the lateral incisors (a, b) (patient W.E.).

In addition to the compact placement of tooth buds or their roots in the alveolar process, when the size of the jaws is insufficient, the alveolar process itself also changes, it is also more compactly located in the area of the tooth buds or roots. If the tooth germ is deep in the alveolar ridge, the shape of the latter on CT in the

"cross-section" may resemble a trapezoid, in which the smaller side is formed by the ridge of the alveolar ridge (Fig. 9).

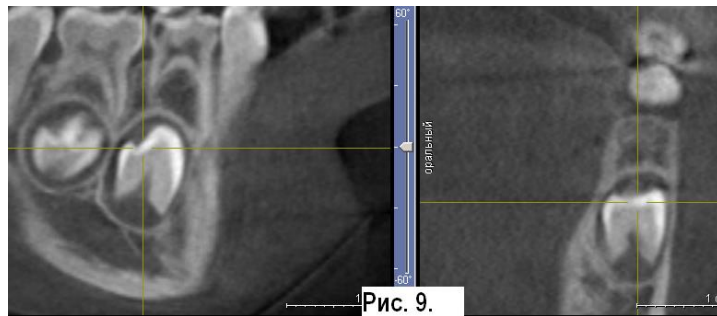


Fig. 9. Trapezoidal form of the alveolar process (patient S.V.).

After the eruption of teeth, the shape of the alveolar ridge in "cross-section" may resemble an hourglass, with a taper located between the root apex and the base of the jaw (Fig. 10).

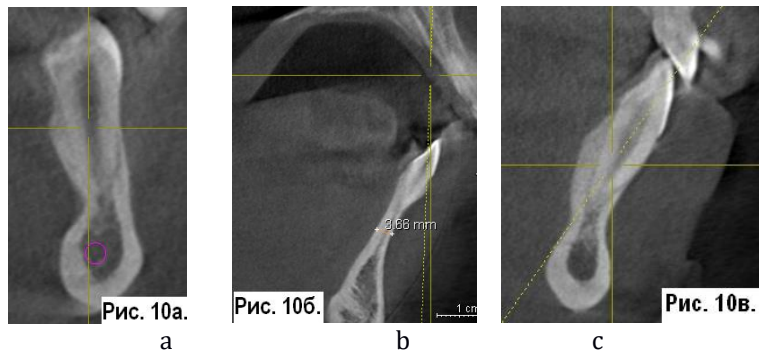


Fig. 10. The shape of the alveolar process in the form of an "hourglass" (a-c) (Fig.10a - patient M.; Fig.10b - patient Z.A. ; Fig.10c - patient K.O.).

During teething, their position is corrected by an individual muscular-articulatory balance. Thus, the vertical axes of the incisors, canines, and chewing teeth on the "CT cross-section" may not coincide with the vertical axis of the alveolar process and have a vestibular or lingual inclination relative to it. Consequently, even in cases of a decrease in the transverse dimensions of the dental arch, due to insufficient size of the jaw, it is biologically "expanded" if the chewing teeth have a vestibular slope (Fig. 11.). An attempt to expand the dental arches using instruments in such cases is futile.

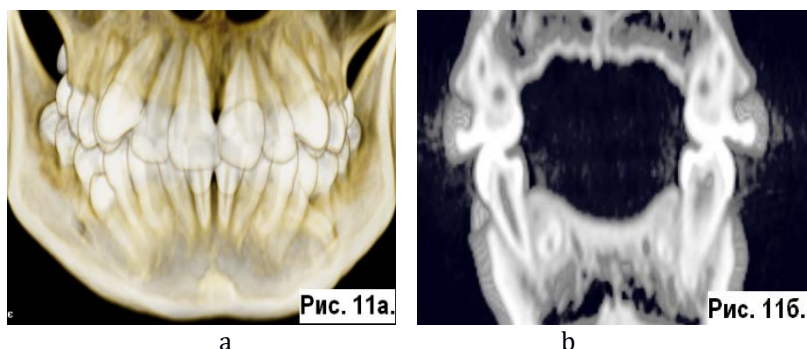


Fig. 11. The vestibular inclination of the chewing teeth (a, b) (patient SN).

With the premature removal of the second primary molars, the teeth surrounding the defect can be tilted-rotationally displaced lingually and towards the defect. Dental arch contraction and blockage of the second premolars may occur (Fig. 12.).

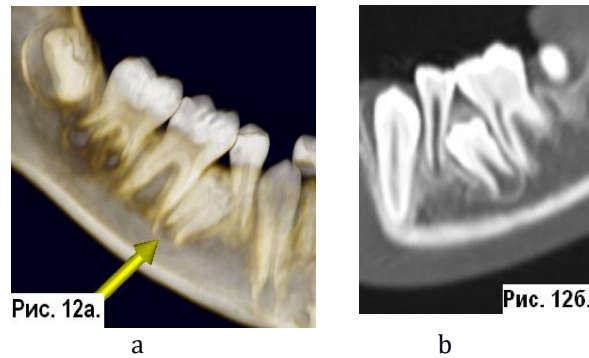


Fig. 12. Blocking of the second premolars (a, b) (patient I.M.).

This reduction in the dental arch is the result of the existing muscular-articulatory balance. In this case, the size of the jaw can be sufficient, and the rudiment of the second premolar is correctly located in the alveolar process. Despite the significant reduction of the dental arch, the apparatus orthodontic creation of space and the normalization of the position of the teeth in such cases is not a difficult task.

The teeth themselves also adapt to the limited space for their formation. The tops of the horses' teeth are curved: the more significant the lack of space, the more of the tooth root is curved. Also, in such cases, there may be a decrease in the length of the roots of the teeth (Fig. 13.).

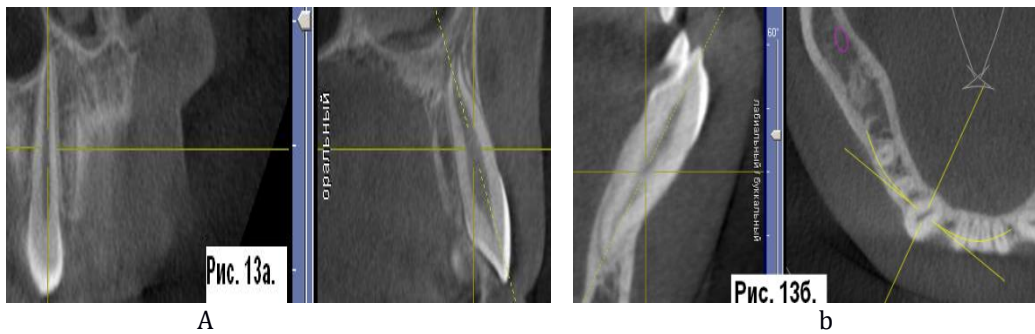


Fig. 13. The curvature of the roots of the teeth due to the insufficient size of the jaws (Fig.13a - patient Z.D.; Fig.13b - patient L.A.).

In this case, the shape of the crowns of the teeth becomes more triangular, the corresponding changes in the incisors are described in the literature. [4] and in the first premolars [2]. The lack of space for the formation of teeth can be due to both insufficient size of the jaws and a compensatory-adaptive change in the position of the teeth (Fig. 14).

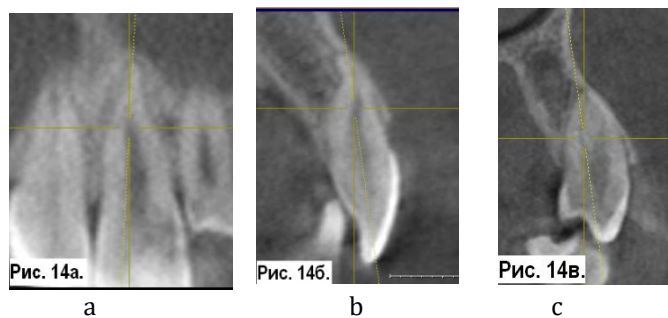


Fig. 14. The curvature of the roots of the teeth due to a compensatory-adaptive change in their position (a-c) (patient G.E.).

The most common of the above is the following symptom: "vestibular inclination of the chewing teeth" - it was found in 632 subjects (35.1%). Thus, if the size of the jaws is insufficient or if they do not match, the dental arches can already be

compensated "expanded". "Curvature of the roots of the teeth due to insufficient size of the jaws" was noted in 195 patients (10.8%), and with a compensatory-adaptive change in the position of the teeth in 43 (2.4%). Insufficiency of the alveolar

bone was combined with tortoanomaly of teeth in 126 patients (7.0%), in 47 - the canines were in tortoanomaly with insufficiency of the alveolar bone behind the lateral incisors (2.6%). The shape of the alveolar process in the form of an "hourglass" had 59 surveyed (3.3%), and in 24 it was trapezoidal (1.3%). The prevalence of the remaining symptoms under consideration was as follows: "the position of the crowns of the primordia of the permanent central incisors behind the roots of the temporal ones of the same name" - 28 subjects (1.6%); "The position of the roots of the lateral incisors behind the roots of the central" - 77 (4.3%); "Dense arrangement of the roots of the incisors" - 75 (4.2%); "Deep position of canine buds" - 48 (2.7%); "Vestibular position of the canines" - 131 (7.3%); "Palatal position of the rudiments of the second premolars" - 62 (3.4%); "Blocking of the second premolars" - 55 (3.1%). "Palatal position of the rudiments of the second premolars" - 62 (3.4%); "Blocking of the second premolars" - 55 (3.1%). "Palatal position of the rudiments of the second premolars" - 62 (3.4%); "Blocking of the second premolars" - 55 (3.1%).

CONCLUSION

The study identified and structured adaptive changes in the dentoalveolar complex to the insufficient size of the jaws and variants of the muscular-articulatory balance. Adaptive changes affect the entire dental alveolar complex. Their manifestations significantly affect the choice of strategy and tactics of orthodontic correction. In turn, orthodontic correction in many cases cannot optimize the condition of the dental alveolar complex.

DISCLOSURE OF INTEREST

the authors declare that they have no competing interests.

REFERENCES

1. Rybakova T.A. Clinical, radiological and rheoparodontological characteristics of the close position of the anterior teeth of the lower jaw: Dis. ... Cand. honey. sciences. - M., 1983.- 139 p.
2. Shishkin K.M., Kolganova S.I. Odontometry data of the first premolar of the upper jaw with the crowded position of teeth and class I and with distal occlusion // *Orthodontics*. - 2009. - vol. 47, No. 3. - S. 24-26.
3. Dannan A. An update on periodontic-orthodontic interrelationships // *J Indian Soc Periodontol*. 2010 Jan; 14 (1): 66-71.
4. Rhee SH, Nahm DS Triangular-shaped incisor crowns and crowding // *American journal of*

orthodontics and dentofacial orthopedics. - 2000. - Vol. 118, no. 6. - P. 624-628.

5. The effects of orthodontic therapy on periodontal health: A systematic review of controlled evidence / AM Bollen, J. Cunha-Cruz, DW Bakko, GJ Huang, PP Hujoel // *J Am Dent Assoc*. 2008; 139: 413-22.
6. The relationships between malocclusion, fixed orthodontic appliances, and periodontal disease: A review of the literature // J. van Gastel, M. Quirynen, W. Teughels, C. Carels // *Aust Orthod J*. 2007; 23: 121-9.