

A Rare Case of Bilateral Sporadic Renal Hemangioblastoma

Ramezan Jafari¹, Alireza Saadat^{2*}, Mohammad Nikpouraghdam^{3*}, Mohammad Javanbakht⁴, Samira Shahverdi⁵, Ayla Jafari⁶, Majid Ershadi⁷

¹Department of Radiology, Baqiyatallah University of Medical Sciences, Tehran, Iran.

²Department of Hematology and Oncology, Baqiyatallah University of Medical Sciences, Tehran, Iran.

³Nephrology and Urology Research Center, Clinical Science Institute, Baqiyatallah University of Medical Sciences, Tehran, Iran.

⁴Nephrology and Urology Research Center, Clinical Science Institute, Baqiyatallah University of Medical Sciences, Tehran, Iran.

⁵Department of Radiology, Baqiyatallah University of Medical Sciences, Tehran, Iran.

⁶School of Pharmacy, Shahid Beheshti University of Medical Sciences, Tehran, Iran.

⁷Anesthesiologist, Farmanieh Hospital, Tehran, Iran.

ABSTRACT

Background: Sporadic renal hemangioblastoma (HB) is an extremely rare malignancy whose progression and prognosis are still unknown.

Case presentation: We describe a rare case of bilateral sporadic renal HB in a 58-year-old male with hematuria and flank pain. The diagnosis of this tumor was confirmed by typical imaging finding and negative immunostaining for cytokeratin (CKAE1/AE3), CD10, CD117, and positive staining for CD31, CD34, Vimentin and Inhibin-A in the biopsy specimen. Major demolitive surgery was avoided and during the subsequent 3 years no change in tumour size nor metastasis were observed.

Conclusions: Immunohistochemistry (IHC) was critical for the differential diagnosis of HB from other more common renal tumours, especially renal cell carcinoma. To the best of our knowledge, this is the first case report of a HB involving both kidneys.

Corresponding Author e-mail: alirezasaadat44@gmail.com, m.nikpoor.doctor@gmail.com

How to cite this article: Jafari R, Cegolon L, Shahverdi S, Javanbakht M, Saadat S, Ershadi M, Einollahi B (2023). An Extremely Rare Case of Bilateral Sporadic Renal Hemangioblastoma. Journal of Complementary Medicine Research, Vol. 14, No. 6, 2023 (pp. 201-203)

BACKGROUND

Sporadic hemangioblastoma is a rare tumor typically occurring in the central nervous system (CNS), especially in the cerebellum and in the spinal (thoracic or cervical) cord [1,2]. Although various organs (soft tissues, bone, liver, lungs, peripheral nerves, pancreas, retroperitoneum, adrenal glands, kidney and urinary bladder) have been reported as potential sites for its onset, the development of hemangioblastoma outside CNS is rather exceptional [3-5].

We report the case of a 58 years old man affected by bilateral sporadic renal hemangioblastoma (HB).

CASE PRESENTATION

Clinical History and Findings

A 58-year-old male with bilateral renal masses was admitted to our radiology department at Baqiyatallah hospital (Teheran, Iran) for further examination. The patient had flank pain and microscopic hematuria. Ultrasound scan (US) showed bilateral iso-echoic masses involving both kidneys, whereas the rest of the urinary tract and bladder was normal, without any mass or stone, prompting the suspicion of a transitional cell carcinoma (TCC) or a renal cell carcinoma (RCC).

On CT scan and MRI with and without contrast two well circumscribed intense enhancing mass are seen in sinus of both kidneys without any obvious invasion to adjacent renal parenchyme compatible with non aggressive hypervascular bilaterall renal mass such as hemangioblastoma wich was an exteremly rare entity, larger diameters of the two renal masses were 30 mm for the right kidney and 19 mm for the left (Figure 1 and 2).

KEYWORDS:

Hemangioblastoma,
Renal Cell Carcinoma,
Immunohistochemistry,
Immunostaining,
Markers.

ARTICLE HISTORY:

Received: Jun 14, 2023

Accepted: Jul 11, 2023

Published: Aug 09, 2023

DOI:

10.5455/jcmr.2023.14.06.20

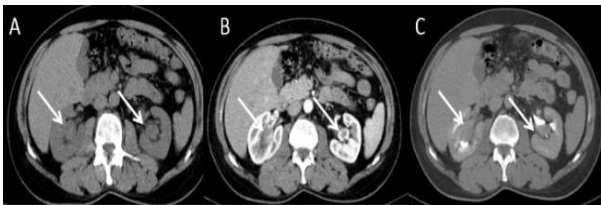


Figure 1: Axial Computerized Tomography (CT) Scan Without Contrast

- A:** Bilateral round soft tissue masses in the renal sinuses (white arrows);
- B:** Peripheral enhancement at nephrogram phase after contrast injection;
- C:** Wash out at pyelogram phase.

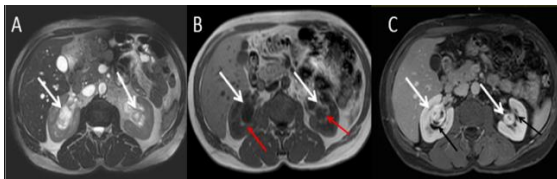


Figure 2: Axial T2 Weighted Magnetic Resonance Imaging (MRI) Showing 2 Masses Separated from the Renal Parenchyma by a Collecting System (Figure B and C, black & red arrows). Furthermore:

- **Figure A:** Round heterogeneously high signal mass in the sinuses of both kidneys (white arrows);
- **Figure B:** Low signal on T1 Weighted MRI;
- **Figure C:** Intense enhancement on post gadolinium MRI.

Axial CT scan did not detect any further extra-renal tumour, and the Brain and orbital magnetic resonance imaging (MRI) was normal and no imaging or clinical evidence of von Hippel-Lindau disease was found.

Since short-interval CT scan follow-up prompted no need of partial nephrectomy, a conservative management was decided. And to date, the patient renal masses have been followed for five years by annual follow up imaging (ultrasound and MRI), during which time they have been stable in size shape and appearance. Instead of a partial nephrectomy, a CT-guided biopsy with a 18 G needle was performed under patient consent which confirmed the diagnosis. Although specimen biopsy has a considerable intrinsic health risk for the patient, surgical specimen series can still be hazardous [6].

Immunohistochemistry and Microscopic Features

The histopathological specimen was suggestive for bilateral renal hemangioblastoma.

Microscopic analysis of the neoplastic tissue evidenced two components, both without cell atypia and mitoses (Figure 3):

- Multiple well-formed endothelial-lined vascular channels, with positive immunoreactivity for CD-31 and CD-34;
- vacuolated foamy clear cells with indistinct cell border and monotonous nuclear between vessels, with negative immunoreactivity for CK AE-1/AE-3, CD-10 and CD-117, positive reaction for Vimentin and strong positive immunoreaction for Inhibin-A (Figure 3). Negative immunoreactions for CKAE1/AE3 and CD10 therefore argued against RCC.

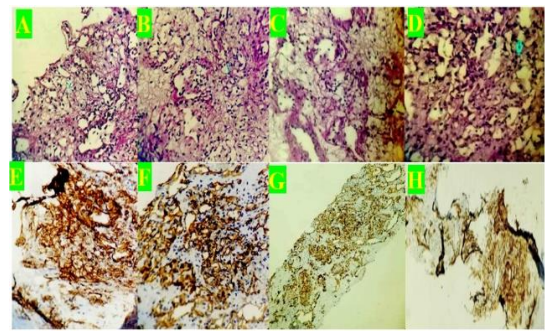


Figure 3: Histopathological Specimen, Indicative of Bilateral Renal Hemangioblastoma

Figures (3A,3B, 3C & 3D) "Right kidney". Tumor cellular areas, mostly composed of vacuolated foamy clear cells and stromal cells with relatively eosinophilic cytoplasm, mainly containing lipid droplets, oval and pleomorphic nuclei and vascular channels surrounding stromal cells in the right and left kidney (Haematoxylin & Eosin stain; magnification 200 x).

Figures (3E,3F,3G & 3H):" Left kidney". Immunohistochemical staining shows that the tumor cells were positive for CD31 and CD34 (Figures 3E and 3F) as well as tumor cells were diffusely positive for Vimentin (Figure 3G) and Inhibin-A (Figure 3H) in the right and left kidney

DISCUSSION

- We presented a rare case of sporadic bilateral renal hemangioblastoma in a 58-year-old man. As far as we are aware, a case of sporadic hemangioblastoma involving both kidneys have never been reported in the open literature to date.
- The decision to opt for a conservative management of the disease was influenced by the location of the tumor and its size. The two tumor masses were completely intra-parenchymal and growing in the renal sinus, an anatomical location featured by high complexity in terms of nephrometry score and by high risk of surgical complications, as compared to low complexity exophytic lesions located in the renal pole, for instance [7].
- As described in the present case, tumoral cells of hemangioblastoma typically have foamy or vacuolated cytoplasm and several endothelial cells form sparse vascular channels. However, differentiating between renal hemangioblastoma and RCC based on cell morphology may be quite challenging, hence IHC markers are the only option [8-10]. In the present case, the application of a IHC panel with CD31, CD34, KAE1/AE3, CD10, CD117, Vimentin and inhibin-A successfully ensured a correct diagnosis. In particular, the latter immunophenotype panel was used as a marker of hemangioblastoma over RCC.
- Whilst immunostaining for CKAE1/AE3, CD-10 and CD-117 all tested negative, CD-31, CD-34, Vimentin and inhibin-A markers were positive. By contrast, RCC is typically negative for α -inhibin and positive for CK AE1/AE3 and CD-10 [8,9,11]. Similar features have been reported by other authors using the same IHC panel on different variants of hemangioblastoma [8,12-16].

Clear cells RCC has been reported to have overlapping histological features with hemangioblastoma, and the distinction between the latter two tumours is not always

straightforward [6,17, 18]. In fact, it is still a debate whether a renal hemangioblastoma should be considered as separate entity or rather a diffuse hemangioblastoma-like differentiation of a clear cells RCC, as endorsed by some authors. Nevertheless, regardless the ultimate histological classification, and despite local tumour complications and symptoms which may justify surgical treatment, hemangioblastoma histological features seem associated with slow growing mass and a more favorable clinical outcome [6]. During the subsequent 3 years no change in tumour size nor metastasis were in fact observed in the above patient.

CONCLUSIONS

In summary, typical imaging finding and IHC panel on a very rare sporadic bilateral renal hemangioblastoma proved critical for the ultimate differential diagnosis of a benign hemangioblastoma over malignant renal tumors - primarily RCC - and the subsequent conservative management of the condition, therefore avoiding major surgery for the patient. The patient was followed up for 3 years, with a CT scan performed every year, and a US scan every 6 months.

Abbreviations

IHC; Immunohistochemistry, CNS: central nervous System, US; Ultrasound scan, HB: hemangioblastoma, TCC: transitional cell carcinoma, RCC: renal cell carcinoma, CK: cytokeratin.

DECLARATIONS

Acknowledgements

Thanks to guidance and advice from “Clinical Research Development Unit of Baqiyatallah Hospital”.

Authors ‘Contributions

All authors contributed equally to this work and performed radiologic analysis, pathological diagnosis, immunohistochemical analysis, assisted writing and native the article. All authors read and approved the final manuscript

Funding

Not applicable.

Availability of Data and Materials

All available data have been shared in the manuscript.

Ethics approval and consent to participate

Not applicable.

Consent for Publication

Written informed consent was obtained from the patient for

publication of this case report and any accompanying images.

Competing Interests

The authors declare that they have no competing interests.

REFERENCES

- Oberhammer L, Mitterberger MJ, Lusuardi L, et al. Sporadic renal hemangioblastoma: A case report of a rare benign renal tumor. *Clin Case Rep.* 2019; 00: 1-6
- Takayanagi S, Mukasa A, Tanaka S, Nomura M, Omata M, Yanagisawa S, et al. Differences in genetic and epigenetic alterations between von Hippel-Lindau disease-related and sporadic hemangioblastomas of the central nervous system. *Neuro Oncol.* 2017;19(9):1228-1236
- Liu Y, Qiu XS, Wang EH. Sporadic hemangioblastoma of the kidney: a rare renal tumor. *Diagn Pathol.* 2012; 7: 49
- Wu Y, Wang T, Zhang PP, Yang X, Wang J, Wang CF. Extraneural hemangioblastoma of the kidney: the challenge for clinicopathological diagnosis. *J Clin Pathol.* 2015;68(12):1020-5
- Jalikus FG, Hoch BL, Bakthavatsalam R, Montenegro MI. Sporadic Retroperitoneal Hemangioblastoma: Report of a Case and Review of the Literature. *Case Rep Pathol.* 2017;2017:4206489.
- Montironi R, Lopez-Beltran A, Cheng L, Galosi AB, Montorsi F, Scarpelli M. Clear Cell Renal Cell Carcinoma (ccRCC) with hemangioblastoma-like features: a previously unreported pattern of ccRCC with Possible Clinical Significance. *Eur Urol* 2014; 66: 806-810
- Dell'Atti L, Scarcella S, Manno S, Polito M, Galosi AB. Approach for Renal Tumors With Low Nephrometry Score Through Unclamped Sutureless Laparoscopic Enucleation Technique: Functional and Oncologic Outcomes. *Clin Genitourin Cancer.* 2018;16(6):e1251-e1256.
- Liu Y, Qiu XS, Wang EH. Sporadic hemangioblastoma of the kidney: a rare renal tumor. *Diagn Pathol.* 2012; 7: 49
- Verine J, Sandid W, Miquel C, Vignaud JM, Mongiat-Artus P. Sporadic hemangioblastoma of the kidney: an underrecognized pseudomalignant tumor? *Am J Surg Pathol.* 2011;35(4):623-4.
- Guo J, Li L, Zhao LH, Li Y, Wang LS, Xiao L, et al. Clinicopathologic characteristics of sporadic renal hemangioblastoma. *Zhonghua Bing Li Xue Za Zhi.* 2013;42(10):679-82.
- Srigley JR, Delahunt B. Uncommon and recently described renal carcinomas. *Mod Pathol.* 2009;22(Suppl 2): S2-S23.
- Luo DY, Zhang J, Tian Y, Zhao ZH. Primary hemangioblastoma of the left kidney and epithelioid leiomyoma of the right. *Int J Clin Exp Pathol* 2016;9(11):12013-12016
- Ip YT, Yuan JQ, Cheung H, Chan JK. Sporadic hemangioblastoma of the kidney: an underrecognized pseudomalignant tumor? *Am J Surg Pathol.* 2010 Nov;34(11):1695-700
- Jiang JG, Rao Q, Xia QY, Tu P, Lu ZF, Shen Q, et al. Sporadic hemangioblastoma of the kidney with PAX2 and focal CD10 expression: report of a case. *Int J Clin Exp Pathol.* 2013;6(9):1953-6
- Zhao M, Williamson SR, Yu J, Xia W, Li C, Zheng J, et al. PAX8 expression in sporadic hemangioblastoma of the kidney supports a primary renal cell lineage: implications for differential diagnosis. *Hum Pathol.* 2013;44(10):2247-55
- Jung SM, Kuo TT. Immunoreactivity of CD10 and inhibin alpha in differentiating hemangioblastoma of central nervous system from metastatic clear cell renal cell carcinoma. *Mod Pathol.* 2005;18(6):788-94
- Sancheti S, Menon S, Mukherjee S, Arun I. Clear cell renal cell carcinoma with hemangioblastoma-like features: A recently described pattern with unusual immunohistochemical profile. *Indian J Pathol Microbiol.* 2015; 58(3): 354-5.
- Doyle L, Fletcher C. Peripheral Hemangioblastoma. *Am J Surg Pathol.* 2014; 38 (1): 119-127.