

# Implant Failure and Changes Between Regenerative Procedure Group and Control Group: A Systematic Review and Meta-analysis

Ali Amiri<sup>1\*</sup>, Aziz Goshaderoo<sup>2</sup>, Pantea Moradinejad<sup>3</sup>, Mohammad Shokri Vahed<sup>4</sup>, Fan Qi<sup>5</sup>

<sup>1</sup>Department of Orthodontics, College of Stomatology, The First Affiliated Stomatological Hospital, Xi'an Jiaotong University, Xi'an 710004, PR China

<sup>2</sup>Department of Prosthodontics, School of Dentistry, Shahid Beheshti University of Medical Sciences, Tehran, Iran

<sup>3</sup>Iranian Association of Periodontology, Tehran, Iran

<sup>4</sup>Department of Periodontics, School of Dentistry, Tehran University of Medical Sciences, Tehran, Iran

<sup>5</sup>Department of Orthodontics, College of Stomatology, The First Affiliated Stomatological Hospital, Xi'an Jiaotong University, Xi'an 710004, PR China

## ABSTRACT

**Objective:** In the esthetic area, immediate implant placement are a great opportunity in modern dentistry. Nevertheless, the outcome was impacted by numerous surgical and prosthetic components. This systematic review and meta-analysis aimed to evaluate immediate implant failure and changes between the regenerative procedure and control groups.

**Methods:** MEDLINE, PubMed, Cochrane Library, Embase, ISI, and Google scholar have been utilized as the electronic databases for performing a systematic literature review between 2010 to March 2021. The quality of the involved studies has been evaluated using the Cochrane tool and assessed by two reviewers. The current systematic review has been carried out with regard to the key consideration of the Preferred Reporting Items for Systematic Reviews and Meta-analysis (PRISMA). The mean difference was used for changes in the crestal bone between baseline and follow-up. Risk ratio with the 95% confidence interval (CI) used for implant failure between test and control groups.

**Results:** 126 potentially relevant titles and abstracts were found during the electronic search. Finally, four publications fulfilled the inclusion criteria required for this systematic review. The Mean difference of changes in the crestal bone between test and control groups of immediate implant placement was 0.62mm (95% CI: 0.31mm, 0.94mm; P=0.00) and heterogeneity found (I<sup>2</sup> = 80.43%; P =0.00).

**Conclusions:** The immediately placed implants with regenerative procedure versus the control group showed the better performance to the changes in the crestal bone.

**Corresponding Author:** draliamiri2020@gmail.com, aliamiri@stu.xjtu.edu.cn, Mobile: +86-2982655450

**How to cite this article:** Amiria A, Goshaderooob A, Moradinejadc P, Vahedd MS, Qi F. Implant Failure and Changes Between Regenerative Procedure Group and Control Group: A Systematic Review and Meta-analysis. Journal of Complementary Medicine Research, Vol. 13, No. 3, 2022 (pp. 109-113).

## INTRODUCTION

Dental implants are a treatment for practical and aesthetic needs.<sup>1</sup> Implant placement for esthetics is one of the most significant challenges for clinicians.<sup>2</sup> In this regard, Schulte and Heimke reported an implant placement in the fresh sockets called 'immediate implant'.<sup>3</sup> Therefore, preoperative conditions that lead to complications should be carefully considered before the immediate implant placement. As a result, alveolar bone reconstruction should be considered for improving performance and aesthetics.<sup>4</sup> Immediately implant placement complications include marginal gap, extraction socket, and minor bone defects. A regenerative method can reduce such bone defects, which is desirable in studies.<sup>5,6</sup>

Moreover, processes regenerating the lost bones and tissues supporting the teeth may reverse several damages from the periodontal disease.<sup>7</sup> Despite the positive outcomes of the immediate implant placement with a restorative process, there are many controversies about the need to perform bone augmentation procedures. Also, studies showed the most successful immediate implant in case of placement without bone grafting.<sup>8,9</sup> About this esthetic area, immediate implant placement has provided great opportunities in modern dentistry. Hence, numerous surgical and prosthetic components have impacted the outcome. Therefore, the present systematic review and meta-analysis aimed to evaluate immediate implant failure and changes between the regenerative procedure and control groups.

### KEYWORDS:

Alveolar Bone Grafting,  
Dental Implantation,  
Dental Prosthesis.

### ARTICLE HISTORY:

Received : Mar 15, 2022  
Accepted : Apr 10, 2022  
Published: Jun 16, 2022

### DOI:

10.5455/jcmr.2022.13.03.24

## METHODS

### Search strategy

Between 2010 and March 2021, electronic databases such as MEDLINE, PubMed, Cochrane Library, Embase, ISI, and Google Scholar were used to perform a systematic literature review. Endnote x8 software has been employed to manage the titles electronically. The search has been done with the keywords “Implant failure OR Implant success OR Implant Survival,” “crestal bone OR MBL OR bone loss,” “dental implants OR implants OR immediate implant OR immediate implant placement,” “maxillary AND mandibular,” and “regenerative procedure OR Bone graft material OR graft.” The current systematic review has been conducted with regard to the Preferred Reporting Items for Systematic Review and Meta-analysis (PRISMA) [10], as well as the PICO or PECO strategy, which are important considerations (Table1).

## SELECTION CRITERIA

### Inclusion Criteria

1. Randomized controlled trial studies, prospective and retrospective cohort investigations, and controlled clinical trials,
2. Used immediate implant placement,
3. Test (with graft) and control group (without graft),
4. In humans
5. In English.

### Exclusion Criteria

1. Case studies, case reports, in vitro, and reviews.
2. Animal studies.

### Extraction of data and analysis method

The data extracted from the study were years, study, sex, study design, range and mean age, sample size, implant diameter, implant length, grafting, and follow-up period. The Cochrane tool was used to evaluate the quality of the studies included<sup>11</sup> and evaluated by two reviewers. The mean difference with the 95% confidence interval (CI), the fixed-effect model, and the inverse-variance method has been used for alterations in crestal bone between the baseline and the follow-up. Risk ratio with a Random effect model, 95 percent confidence interval (CI), and restricted maximum-likelihood (REML) method has been used for implant failure between the test and control groups. One of the software programs (Comprehensive Meta-Analysis Stata. 16) was used to evaluate the meta-analysis of forest plots.

**Table1:** PICO OR PECO strategy

PICO OR PECO strategy	Description
P	Population/ Patient: All Patients that received the implant
E	Exposure/ Intervention: immediate implant placement
C	Comparison: with graft vs. without graft
O	Outcome: changes in the crestal bone and implant failure

## RESULTS

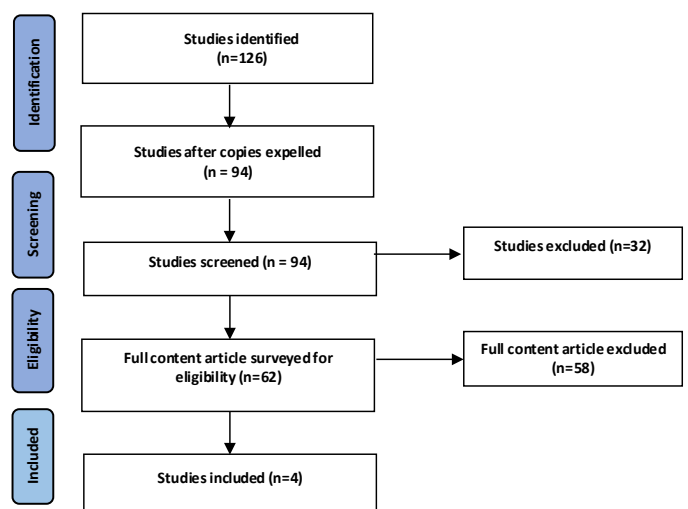
During the electronic searches, 126 potentially significant abstracts and titles were discovered. Amid the primary phase of the study choice, 32 publications have been prohibited with regard to the titles and abstracts. Regarding the moment stage, complete full-text papers of the remained 62 publications have been completely assessed. Thus, 58 articles have been excluded since they could not satisfy our inclusion criteria. At last, four researches satisfied our criteria (Figure 1).

Four randomized clinical trial studies have been considered in the present systematic review and meta-analysis. As a result, 93 patients in the test group and 86 in the control group (total number = 179) with a mean age of 50 participated in this study. The follow-up period ranged from 4 to 9 months (Table 2).

Moreover, Table 1 reports the implant diameter and length. The Cochrane tool evaluated the risk of bias in the included studies, showing that most of the studies had a high, unknown risk of bias (Figure 2). The tool included allocation concealment, random sequence generation, outcome assessment blinding, participant and personal blinding, selective reporting, and incomplete outcome data. The odds ratio of the implant failure between the test group and control group has been -0.56 (95% CI: -2.34, 1.22; P=0.54), which showed heterogeneity (I2 = 0%; P =0.95) (Figure 3). There has been no statistically significant difference between the two groups. The success rate has been reported to be approximately 100%. The mean difference of changes in the crestal bone between test and control groups of the immediate implant placement equaled 0.62 mm (95% CI: 0.31mm, 0.94 mm; P=0.00), which showed heterogeneity (I2 = 80.43%; P =0.00) (Figure 4). This result showed a statistically significant change between the immediate implant placement and the regenerative procedure in the crestal bone and the immediate implant placement without the regenerative procedures.

## DISCUSSION

It has been found that there has been a regular association between the immediate placement of an implant following tooth extraction and the residual bone defects between the surface of the implant and the around bone walls. Many clinical



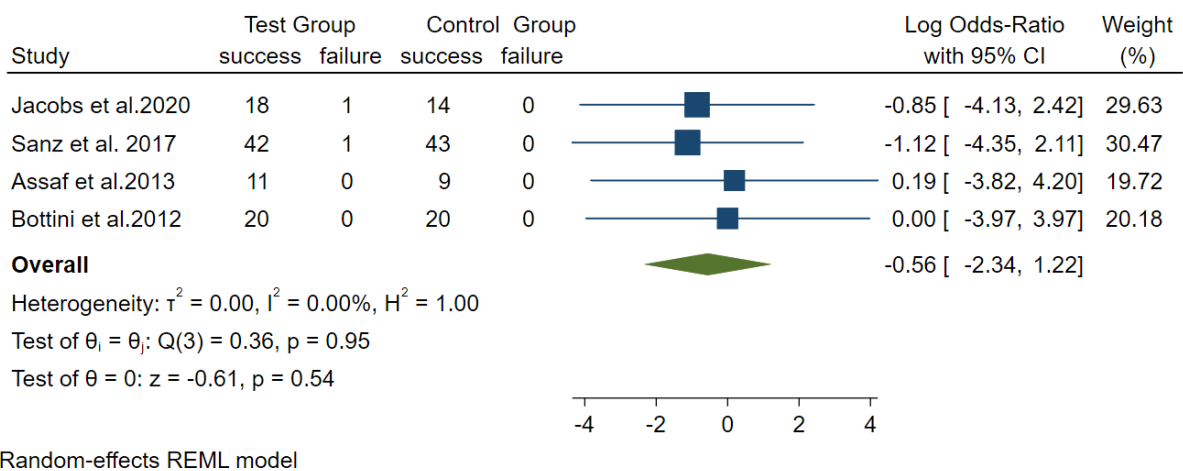
**Fig. 1:** Study Attrition Diagram

**Table 2:** The following studies were selected for a systematic review and meta-analysis

Year of study	Research design	Sample size				Mean-Range of Age (years)	Implant diameter (mm)		Implant length (mm)		Grafting	Follow-up (mean)
		T		C			T	C	T	C		
		M	F	M	F							
Jacobs et al. 2020 (12)	RCT	8	11	6	8	53	4.5: 19	4.5: 14	11:6 13:9 15:4	11:1 13:10 15:3	DBB	10
Sanz et al. 2017 (13)	RCT	22	21	19	24	NR	3.5:6 4.0:37	3.5:5 4.0:38	-	-	DBBM-C	4
Assaf et al. 2013(14)	RCT	11		9		48.5	4.1:11	4.1:9	-	-	BCP	6
Bottini et al. 2012(15)	RCT	14	6	9	11	65.45	3.75:5 4.2:11 5:4	3.75:3 4.2:11 5:6	11.5:7 13:5 10:8	11.5:10 13:4 10:6	Porcine bone	6

Studies	Generating a random sequence	Allocation concealment	Blinding of the patients and employees	Blinding of outcomes' evaluation	Incomplete outcome data	Selective reporting
Jacobs et al.2020	+	?	-	?	-	+
Sanz et al. 2017	?	?	?	?	-	+
Assaf et al.2013	+	?	?	?	+	+
Bottini et al.2012	+	?	-	-	+	+

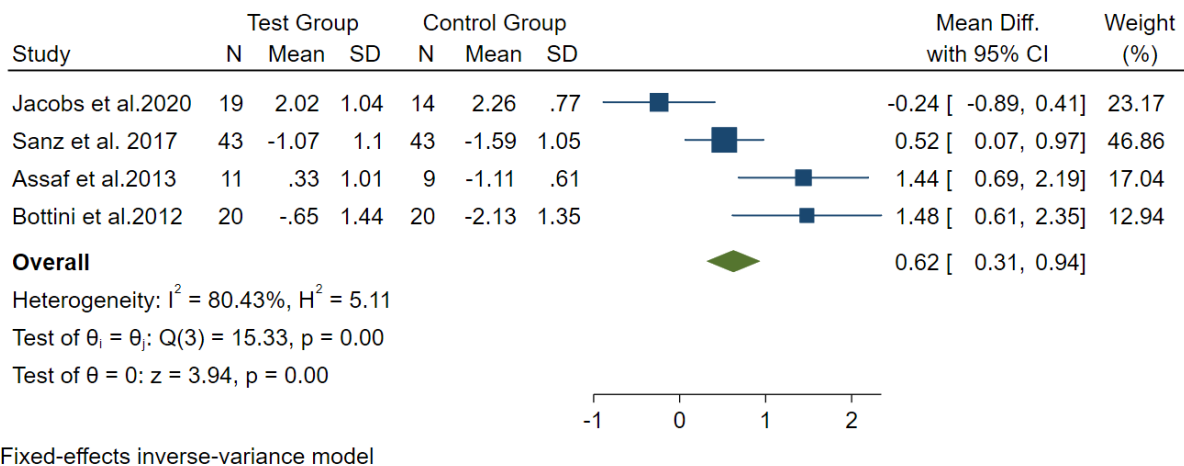
**Fig. 2:** Risk of bias for the randomized clinical trial studies selected for systematic review and meta-analysis. (+) Low risk of bias (-) High risk of bias (?) Unclear risk of bias.



**Fig. 3:** Forest plots showed the odds ratio of implant failure between the test and control groups.

investigations and experimental research have shown an optimal result of the implants, which have been immediately placed in the freshly extracted packages connected with or without restorative substances.<sup>16, 17</sup> Nonetheless, various parameters

can affect the absorption of lingual and buccal bone like the diameter of the implants, residual alveolar crest dimension, surgical procedure, and implant surface topography.<sup>18-20</sup> The current systematic review and meta-analysis results revealed



**Fig. 4:** Forest plots showed a mean difference in changes in the crestal bone between the two groups.

no statistically significant differences in the failure of an implant between the immediate implant placement and the regenerative procedure and without a regenerative procedure ( $p=0.54$ ). Moreover, there have been statistically significant crestal bone changes between the two groups ( $p=0.00$ ). In Bottini et al.<sup>15</sup> Each patient had a single implant implanted with a flapless method into an immediate extraction site of a molar or first upper premolar. To fill the gaps between the implant and the extraction socket in the tests, a deantigenated collagenated bone substitute of porcine origin was used. At the same time, no grafting material was employed in the control sites. The buccolingual bone width was measured at four different times: before surgery (T0), 90 days (T1), 110 days (T2), and six months after masticatory function (T3). The distance between the coronal border of the buccal bone and lingual bone was statistically significant between the test and the control groups. Also, the mean-value declined in the course of observation time in each group.

In Jacobs et al.'s (2020) study,<sup>12</sup> at the flapless, one-stage placement of a sloped-platform implant, immediate implant placement with or without the addition of an organic xenograft is possible. The primary outcome of Jacobs et al.'s (2020) study<sup>12</sup> showed no difference between the two groups (no graft:  $1.47 \pm 0.85$  mm, graft:  $1.63 \pm 0.71$  mm,  $P=.950$ ) of the thickness of the facial crestal alveolar bone; however, secondary outcomes showed no difference between two groups in terms of including pink esthetic score. Sanz et al. 2017.<sup>13</sup> Following an immediate implant in the new extraction sockets, a bovine bone mineral with 10% collagen in the horizontal bone resorption changes in the buccal bone were significantly reduced using the (DBBM-C) bone replacement graft. Direct bone measurements with a periodontal probe were used to analyze the horizontal and vertical crestal bone changes in relation to the implant between implant placement and 16 weeks later. Furthermore, there was a 1.1 mm reduction (29%) in the test group and a 1.6 mm reduction (38%) in the control group. In Assaf et al.<sup>14</sup>, measurements were performed before and six months following extractions and immediate implant implantation in this study. In the test group, biphasic calcium phosphate was discovered in the space between the buccal wall of the alveolar ridge and the implant. The same evaluations and procedures were carried out in the control group but without biphasic calcium phosphate. The result showed no significant differences in the

test group after a 6-month follow-up following surgery, and there have been statistically significant differences in the control group with a reduction from  $8.12 \pm 0.7$  mm to  $7.01 \pm 0.4$  mm. For repairing the bone surrounding the implant, it has been possible to use the immediate implant placement with a regenerative procedure. Another systematic review and meta-analysis performed by Lee et al. [5] showed the same implant survival of both test and control groups. Figure 3 presents the estimates of the same result.

The present study had limitations that need to be considered. Most investigations involve the small size of the samples, and a short period of follow-up included less than one year of follow-up. Future studies are recommended to perform randomized controlled trials with the control group, consisting of higher sample size and longer follow-up periods, and investigate the effects of bone graft on the successfulness and survival of the implant.

## CONCLUSION

According to the analyses, the immediate implant placement with the regenerative procedures outperformed the control group to the modifications in the crestal bone. The implant failure between the two groups showed no statistically significant differences, but it can be said that implant failure was more in the test group.

## ACKNOWLEDGEMENTS

This research received no specific grant from any funding agency in the public, commercial, or not-for-profit sectors.

### Authorship contributions

**Ali Amiri:** Conceptualization, Methodology, Formal Analysis, Investigation, Writing - Original Draft, Writing - Review and Editing and Visualization.

**Aziz Goshaderoo:** Data analysis, Methodology, Writing - Original Draft and Writing - Review and Editing.

**Pantea Moradinejad:** Methodology, Writing - Original Draft and Writing - Review and Editing..

**Mohammad Shokri Vahed:** Validation and Writing - Review and Editing.

**Fan Qi:** Validation and Writing - Review and Editing.

**Ethical approval**

In this systematic review and meta-analysis article is not applicable.

**Informed Consent**

In this systematic review and meta-analysis article is not applicable.

**REFERENCES**

- Kour, N., & Sharma, S. (2021). Assessing the Effects of L-PRF on the Peri-implant Soft and Hard Tissue Parameters in Immediate Implants: A Randomised Controlled Trial. *International Journal of Scientific Research in Dental and Medical Sciences*, 3(4), 156-160. doi: 10.30485/ijstdms.2021.301525.1186.
- Azzaldeen A, Georges C, Nikos K, Muhamad AH. Zirconium Dental Implants And Crown for Congenitally Missing Maxillary Lateral; Clinical Case. *Journal of Dental and Medical Sciences*. 2017;16(3):72-7. DOI: 10.9790/0853-1603137277.
- Dhami B, Shrestha P, Gupta S, Pandey N. Immediate Implant Placement: Current Concepts. *Journal of Nepalese Society of Periodontology and Oral Implantology*. 2019 Sep 20;3(1):18-24. <https://doi.org/10.3126/jnspoi.v3i1.24823>.
- Redemagni M. Post-Extractive Immediate Implant Placement and Immediate Provisionalization at Sites Requiring Buccal Bone Regeneration: A Clinical Case Series. *EC Dental Science*. 2019;18:1207-16.
- Lee J, Park D, Koo KT, Seol YJ, Lee YM. Validity of a regenerative procedure for a minor bone defect with immediate implant placement: a systematic review and meta-analysis. *Acta Odontologica Scandinavica*. 2019 Feb 17;77(2):99-106. <https://doi.org/10.1080/00016357.2018.1508743>.
- Rim, K., Ameni, C., Garrach, B., Chaouch, M. H., & Touzi, S. (2021). Anatomical Dimension of the Anterior Maxillary Alveolar Process: A Cone Beam Computed Tomography Study. *International Journal of Scientific Research in Dental and Medical Sciences*, 3(3), 111-116. DOI: 10.30485/ijstdms.2021.289617.1167.
- Martin I, Jakob M, Schaefer DJ. From Tissue Engineering to Regenerative Surgery. *EBioMedicine*. 2018 Feb 1;28:11-2.
- Atalay B, Öncü B, Emes Y, Bultan Ö, Aybar B, Yalçın S. Immediate implant placement without bone grafting: a retrospective study of 110 cases with 5 years of follow-up. *Implant dentistry*. 2013 Aug 1;22(4):360-5. doi: 10.1097/ID.0b013e31828edd02.
- Bersani E, Ricciardi Coppede A, Prata HH. Immediate loading of implants placed in fresh extraction sockets in the molar area with flapless and graftless procedures: A case series. *The International journal of periodontics & restorative dentistry*. 2010 Jun;30(3): 291.
- Panic N, Leoncini E, De Belvis G, Ricciardi W, Boccia S. Evaluation of the endorsement of the Preferred Reporting Items for Systematic reviews and Meta-Analysis (PRISMA) statement on the quality of published systematic review and meta-analyses. *Stefania Boccia. European Journal of Public Health*. 2013 Oct 1;23. <https://doi.org/10.1093/eurpub/ckt124.018>.
- Higgins JP, Altman DG, Gøtzsche PC, Jüni P, Moher D, Oxman AD, Savović J, Schulz KF, Weeks L, Sterne JA. The Cochrane Collaboration's tool for assessing risk of bias in randomised trials. *Bmj*. 2011 Oct 18;343:d5928. doi: 10.1136/bmj.d5928.
- Jacobs BP, Zadeh HH, De Kok I, Cooper L. A Randomized Controlled Trial Evaluating Grafting the Facial Gap at Immediately Placed Implants. *International Journal of Periodontics & Restorative Dentistry*. 2020 May 1;40(3).
- Sanz M, Lindhe J, Alcaraz J, Sanz-Sanchez I, Cecchinato D. The effect of placing a bone replacement graft in the gap at immediately placed implants: a randomized clinical trial. *Clinical oral implants research*. 2017 Aug;28(8):902-10. <https://doi.org/10.1111/clr.12896>.
- Assaf JH, Zanatta FB, de Brito Jr RB, Gomes França FM. Computed tomographic evaluation of alterations of the buccolingual width of the alveolar ridge after immediate implant placement associated with the use of a synthetic bone substitute. *International Journal of Oral & Maxillofacial Implants*. 2013 Jun 1;28(3).
- Bottini LP, Ricci L, Piattelli A, Perrotti V, Iezzi G. Bucco-Lingual Crestal Bone Changes Around Implants Immediately Placed in Fresh Extraction Sockets in Association or not With Porcine Bone: A Non-Blinded Randomized Controlled Trial in Humans. *Journal of periodontology*. 2012 Oct. DOI: 10.1902/jop.2012.120396.
- Schwartz-Arad D, Chaushu G. The ways and wherefores of immediate placement of implants into fresh extraction sites: a literature review. *Journal of Periodontology*. 1997 Oct;68(10):915-23. <https://doi.org/10.1902/jop.1997.68.10.915>.
- Covani U, Chiappe G, Bosco M, Orlando B, Quaranta A, Barone A. A 10-year evaluation of implants placed in fresh extraction sockets: A prospective cohort study. *Journal of periodontology*. 2012 Oct;83(10):1226-34. <https://doi.org/10.1902/jop.2012.110583>.
- Araujo MG, Wennström JL, Lindhe J. Modeling of the buccal and lingual bone walls of fresh extraction sites following implant installation. *Clinical oral implants research*. 2006 Dec;17(6):606-14. <https://doi.org/10.1111/j.1600-0501.2006.01315.x>.
- Montero J, Bravo M, Guadilla Y, Portillo M, Blanco L, Rojo R, Rosales-Leal J, López-Valverde A. Comparison of Clinical and Histologic Outcomes of Zirconia Versus Titanium Implants Placed in Fresh Sockets: A 5-Month Study in Beagles. *International Journal of Oral & Maxillofacial Implants*. 2015 Jul 1;30(4).
- Vignoletti F, Discepoli N, Müller A, De Sanctis M, Muñoz F, Sanz M. Bone modelling at fresh extraction sockets: immediate implant placement versus spontaneous healing. An experimental study in the beagle dog. *Journal of clinical periodontology*. 2012 Jan;39(1):91-7. <https://doi.org/10.1111/j.1600-051X.2011.01803.x>.